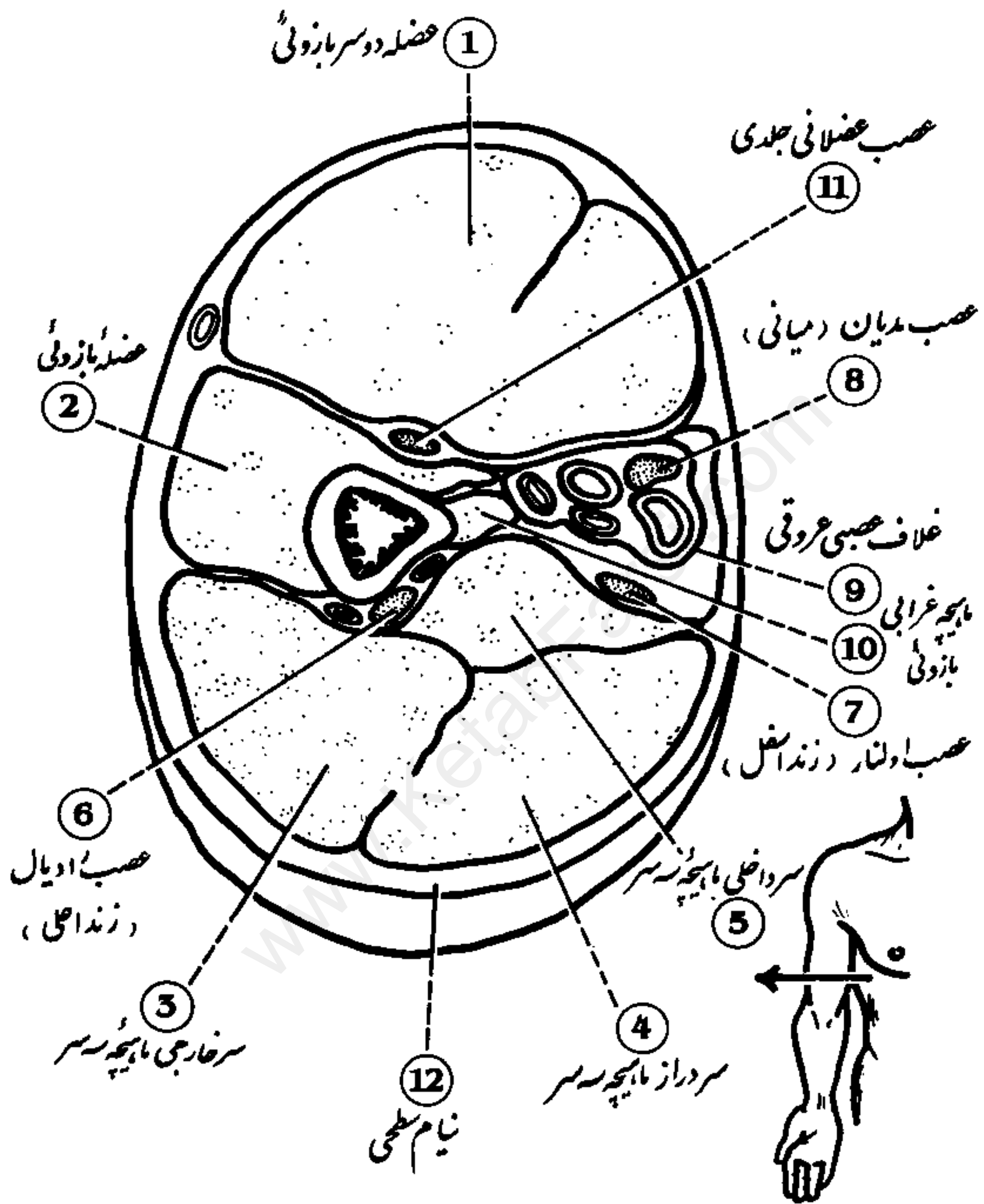


Cross Section of Arm برش عرضی بازو

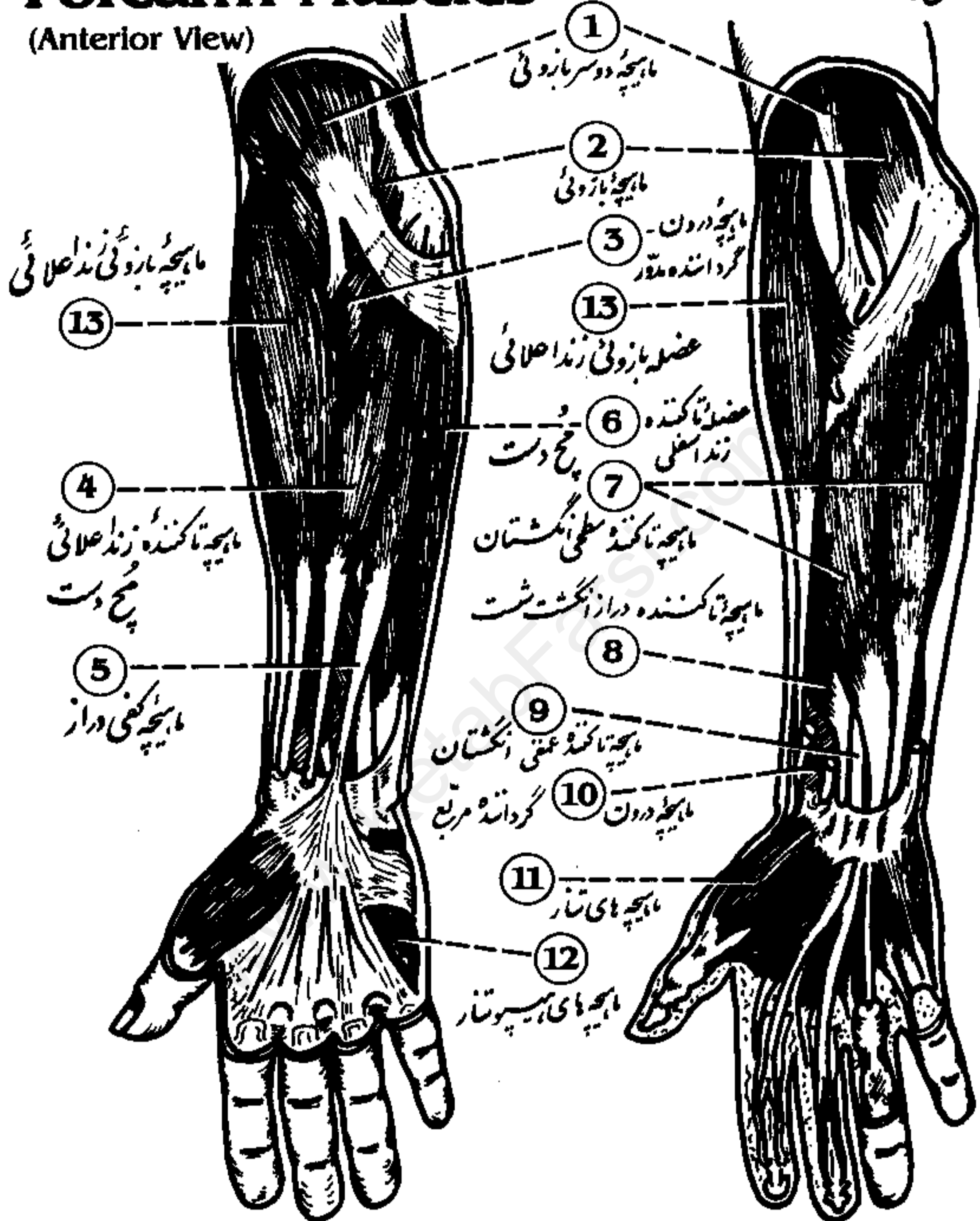


- | | | |
|-------------------------|------------------------|---------------------------|
| 1 Biceps brachii | 5 Triceps, medial head | 9 Neurovascular sheath |
| 2 Brachialis | 6 Radial nerve | 10 Coracobrachialis |
| 3 Triceps, lateral head | 7 Ulnar nerve | 11 Musculocutaneous nerve |
| 4 Triceps, long head | 8 Median nerve | 12 Superficial fascia |

Superficial and Deep Forearm Muscles

عضلات سطحی و عمقی ساعد
(نمای قدامی)

(Anterior View)



1 Biceps brachii

2 Brachialis

3 Pronator teres

4 Flexor carpi radialis

5 Palmaris longus

6 Flexor carpi ulnaris

7 Flexor digitorum superficialis

8 Flexor pollicis longus

9 Flexor digitorum profundus

10 Pronator quadratus

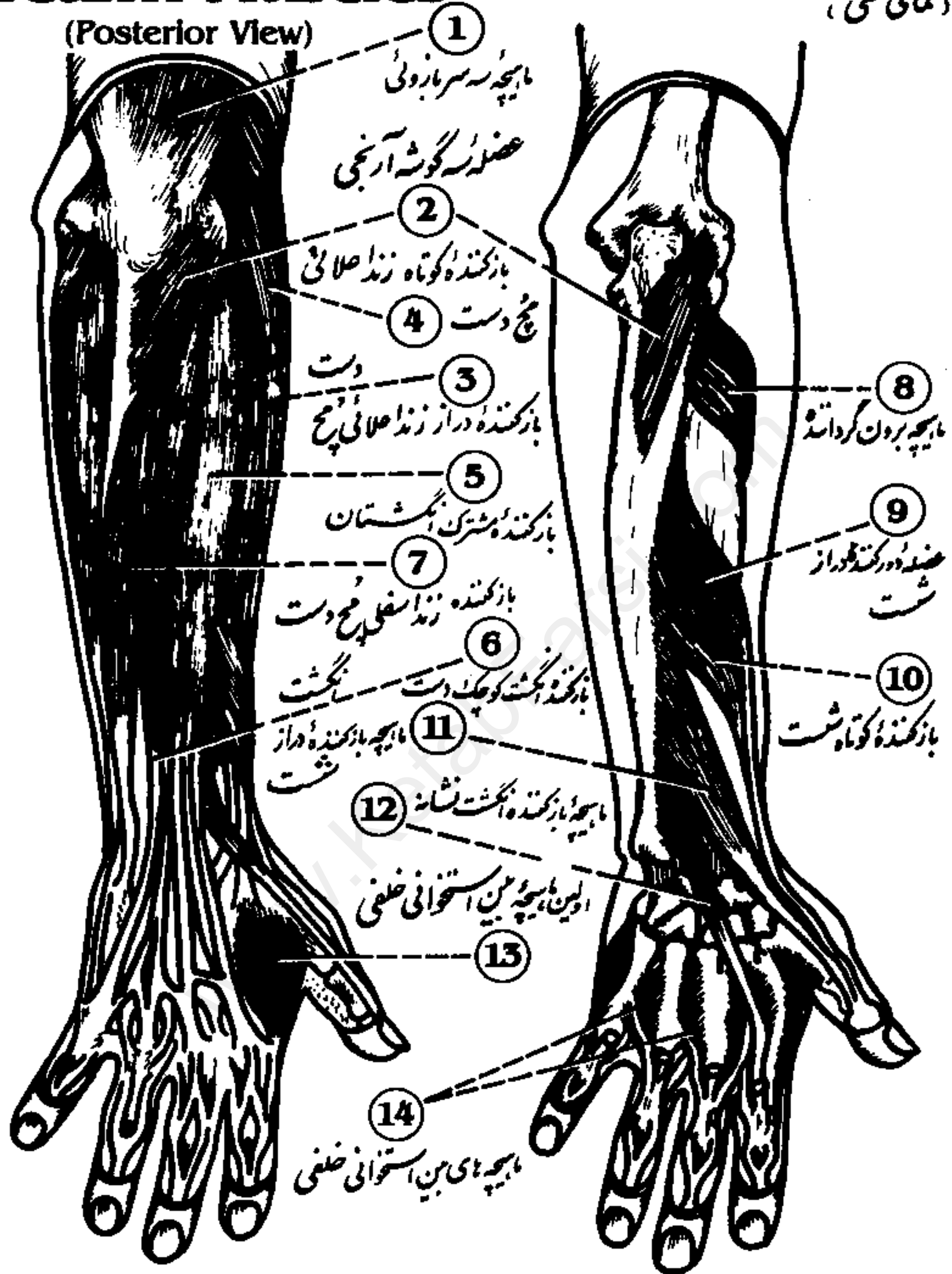
11 Thenar muscles

12 Hypothenar muscles

13 Brachioradialis

Superficial and Deep Forearm Muscles

عضلات سطحی و عمقی ساعد
(نمای خلفی)



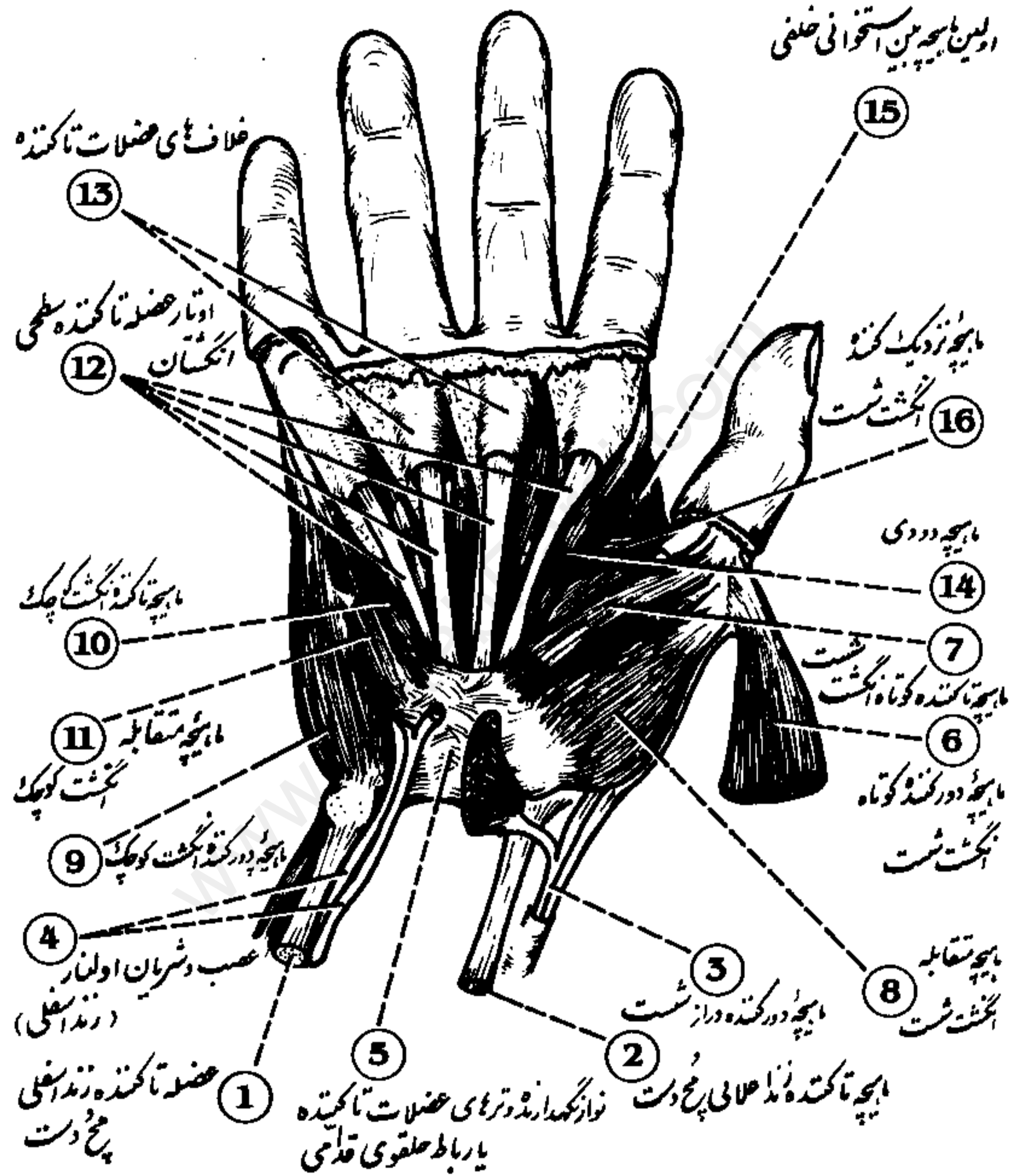
- 1 Triceps brachii
- 2 Anconeus
- 3 Extensor carpi radialis longus
- 4 Extensor carpi radialis brevis
- 5 Extensor digitorum communis

- 6 Extensor digiti minimi
- 7 Extensor carpi ulnaris
- 8 Supinator
- 9 Abductor pollicis longus
- 10 Extensor pollicis brevis

- 11 Extensor pollicis longus
- 12 Extensor indicis proprius
- 13 First dorsal interosseus
- 14 Dorsal interossei

Palm of the Hand

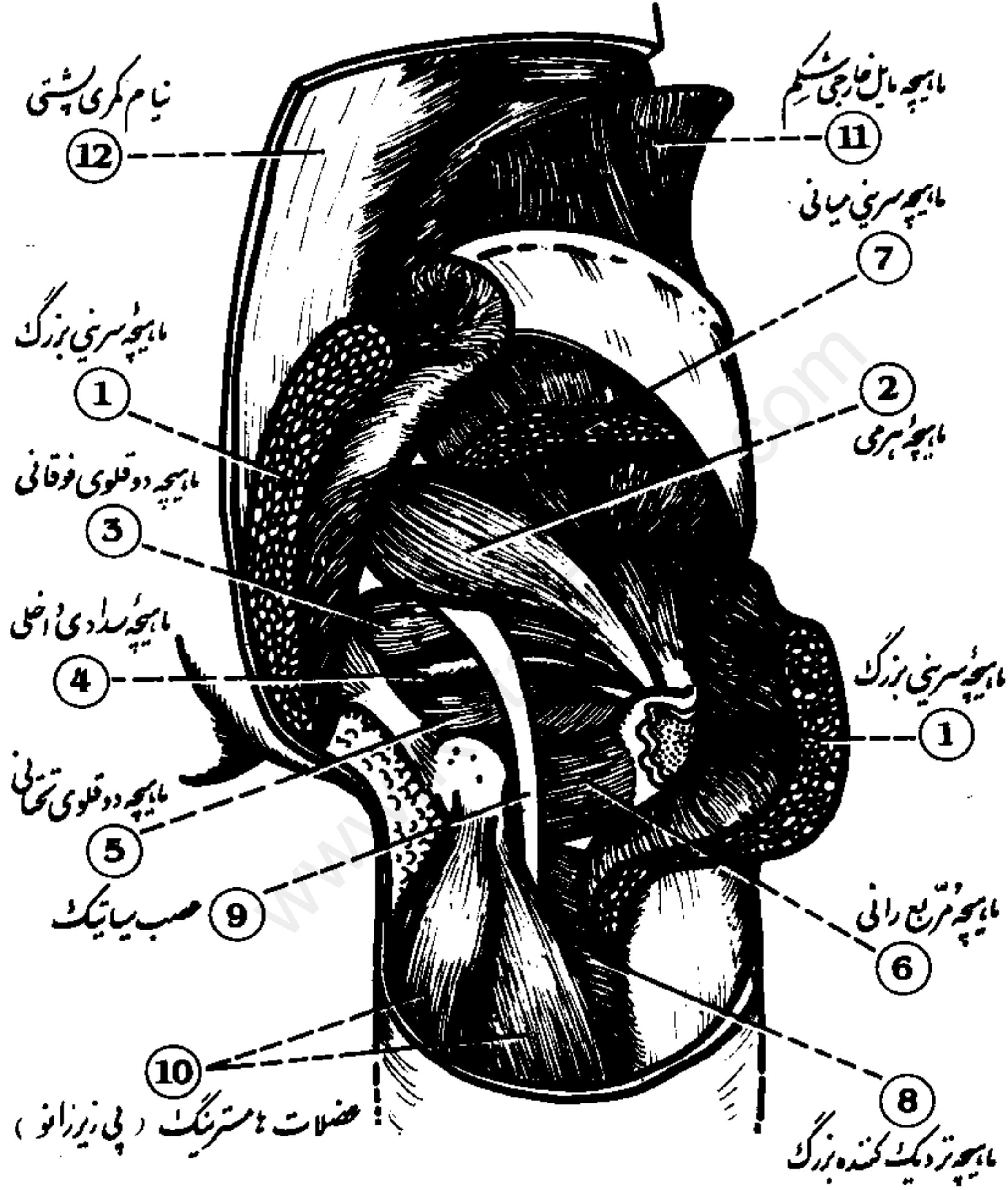
دکف دست



- | | | | |
|----------------------------|----------------------------|-----------------------------|------------------------------|
| 1 Flexor carpi ulnaris | 5 Flexor retinaculum | 9 Abductor digiti minimi | 13 Flexor sheaths |
| 2 Flexor carpi radialis | 6 Abductor pollicis brevis | 10 Flexor digiti minimi | 14 Lumbrical muscle |
| 3 Abductor pollicis longus | 7 Flexor pollicis brevis | 11 Opponens digiti minimi | 15 First dorsal interosseous |
| 4 Ulnar nerve and artery | 8 Opponens pollicis | 12 Flexor digitorum tendons | 16 Adductor pollicis |

Deep Posterior Muscles of the Hip

عضلات عمقی خلفی کفل



- 1 Gluteus maximus
- 2 Piriformis
- 3 Superior gemellus
- 4 Obturator internus

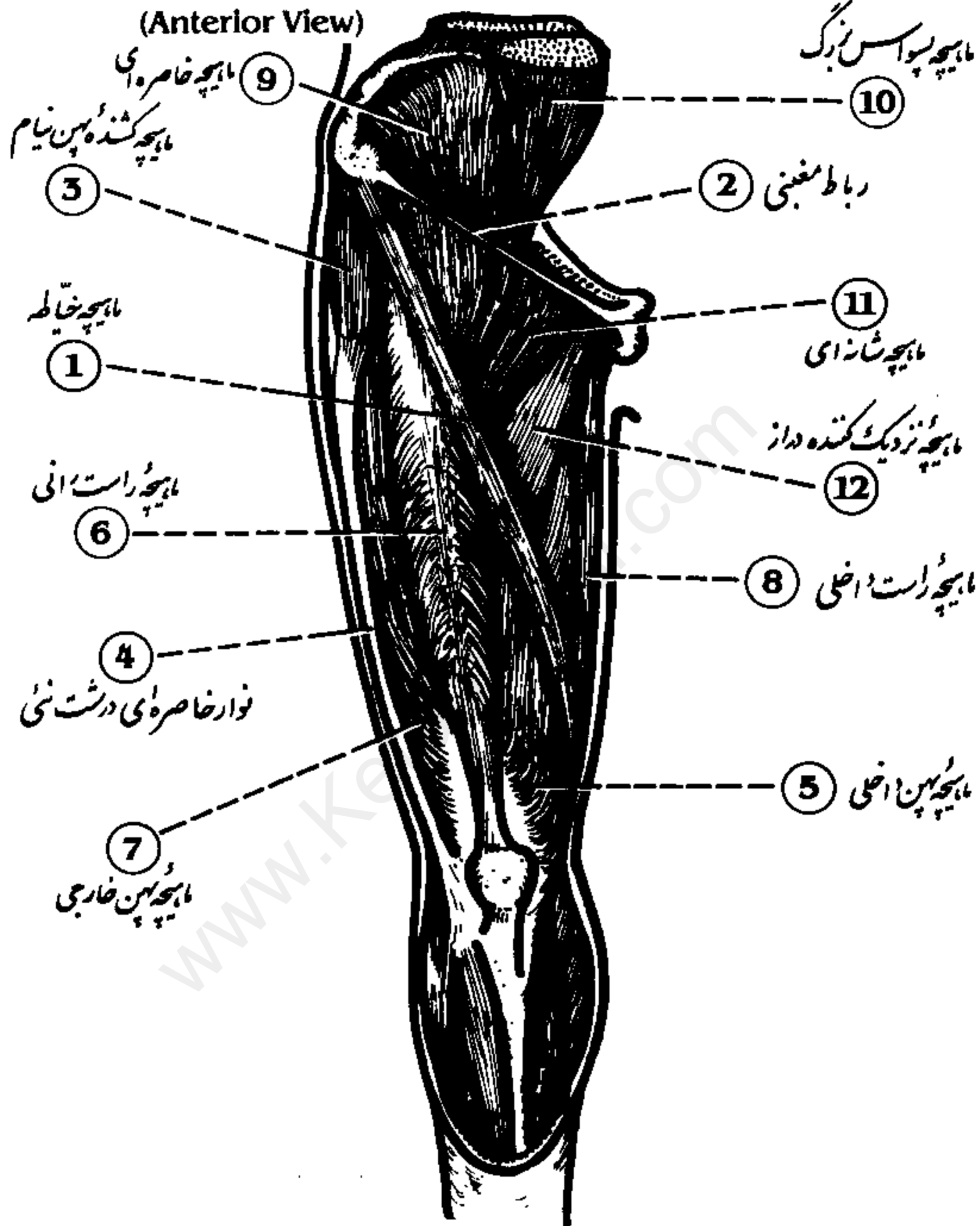
- 5 Inferior gemellus
- 6 Quadratus femoris
- 7 Gluteus medius
- 8 Adductor magnus

- 9 Sciatic nerve
- 10 Hamstring muscles
- 11 External abdominal oblique
- 12 Lumbodorsal fascia

Superficial Thigh Muscles

ماهیچه های سطحی ران ، نمای قدامی

(Anterior View)



1 Sartorius

2 Inguinal ligament

3 Tensor fascia latae

4 Iliotibial band

5 Vastus medialis

6 Rectus femoris

7 Vastus lateralis

8 Gracilis

9 Iliacus

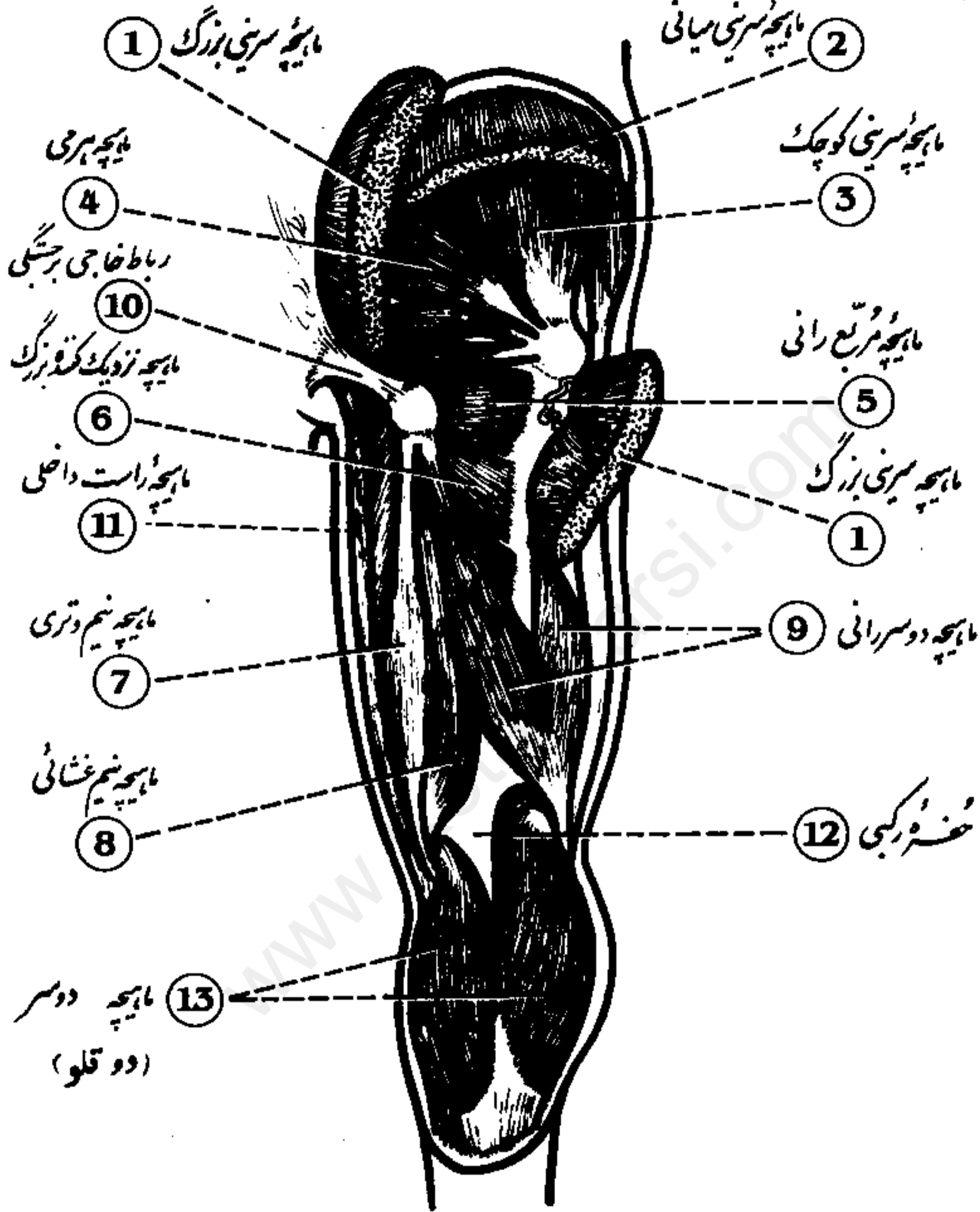
10 Psoas major

11 Pectineus

12 Adductor longus

Posterior Muscles of the Hip and Thigh

(عضلات خلفی گھٹن و ران)

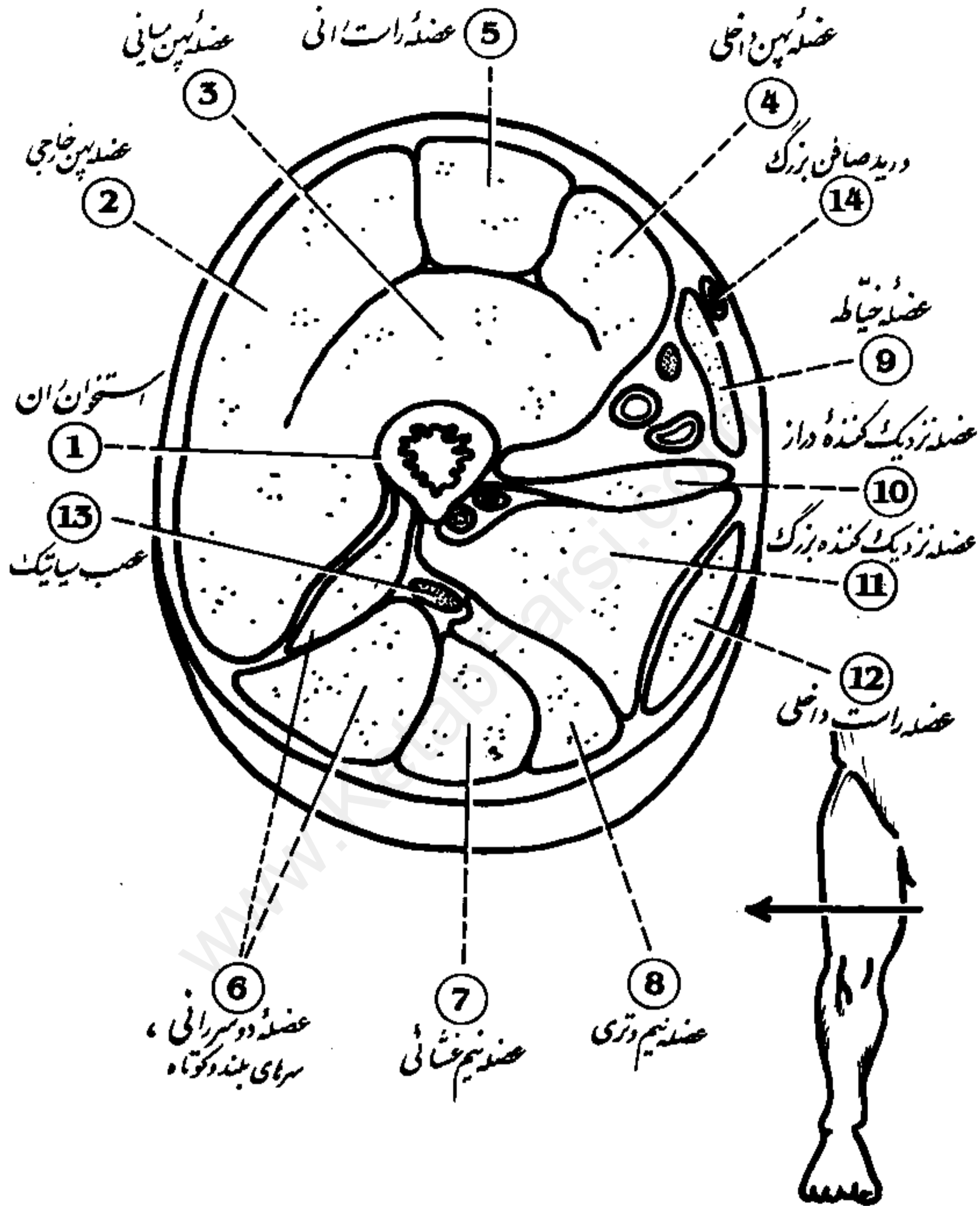


- 1 Gluteus maximus
- 2 Gluteus medius
- 3 Gluteus minimus
- 4 Piriformis
- 5 Quadratus femoris

- 6 Adductor magnus
- 7 Semitendinosus
- 8 Semimembranosus
- 9 Biceps femoris
- 10 Sacrotuberous ligament

- 11 Gracilis
- 12 Popliteal fossa
- 13 Gastrocnemius

دبرش عرضی ران Cross Section of Thigh

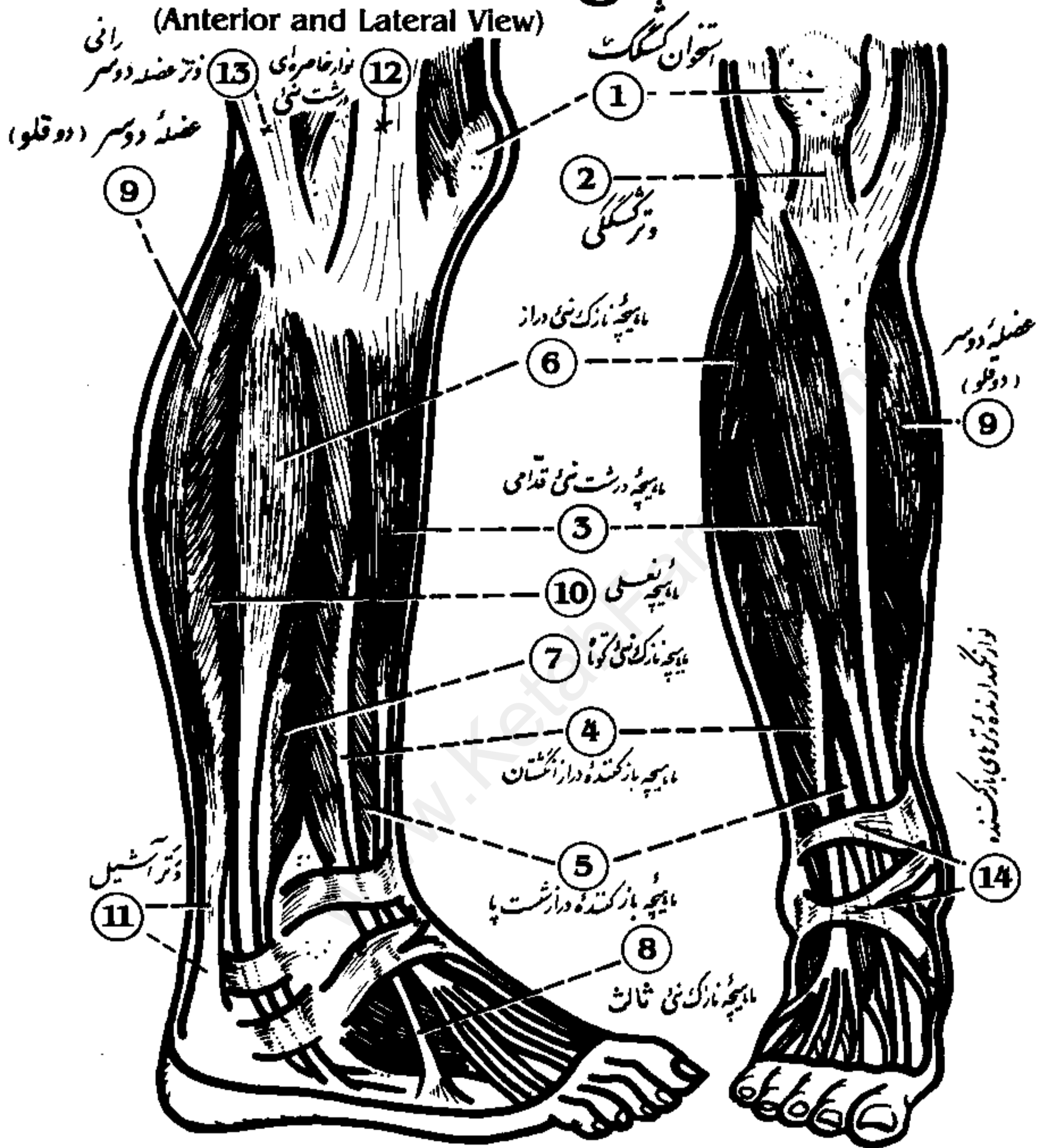


- | | | |
|----------------------|---------------------------------------|-------------------------|
| 1 Femur | 6 Bicep femoris, long and short heads | 11 Adductor magnus |
| 2 Vastus lateralis | 7 Semimembranosus | 12 Gracilis |
| 3 Vastus intermedius | 8 Semitendinosus | 13 Sciatic nerve |
| 4 Vastus medialis | 9 Sartorius | 14 Great saphenous vein |
| 5 Rectus femoris | 10 Adductor longus | |

Superficial Muscles of the Leg

ماهیچه های سطحی ساق پا (نمای قدامی و خارجی)

(Anterior and Lateral View)



1 Patella

2 Patellar tendon

3 Tibialis anterior

4 Extensor digitorum longus

5 Extensor hallucis longus

6 Peroneus longus

7 Peroneus brevis

8 Peroneus tertius

9 Gastrocnemius

10 Soleus

11 Achilles tendon

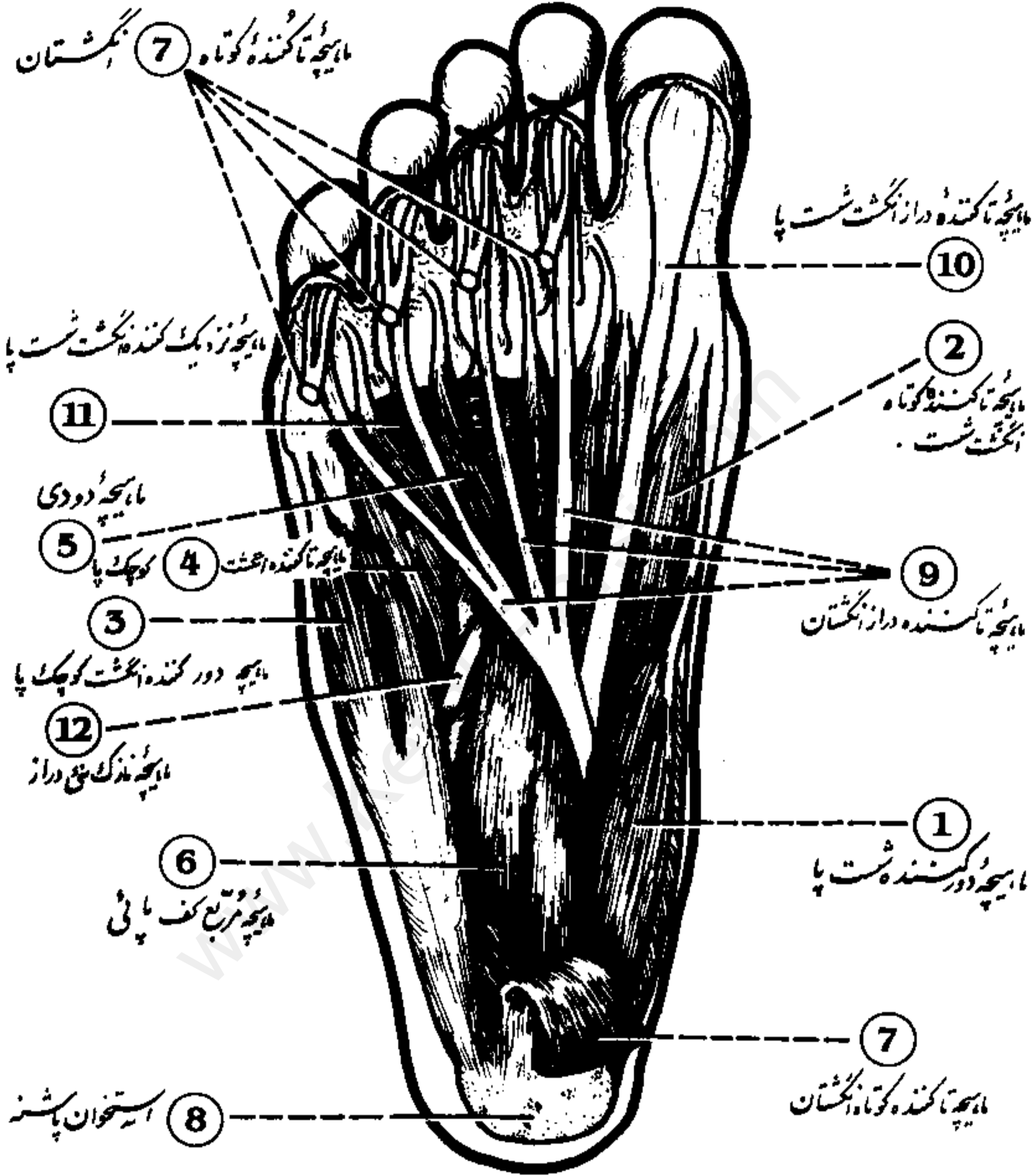
12 Iliotibial band

13 Biceps femoris

14 Extensor retinacula

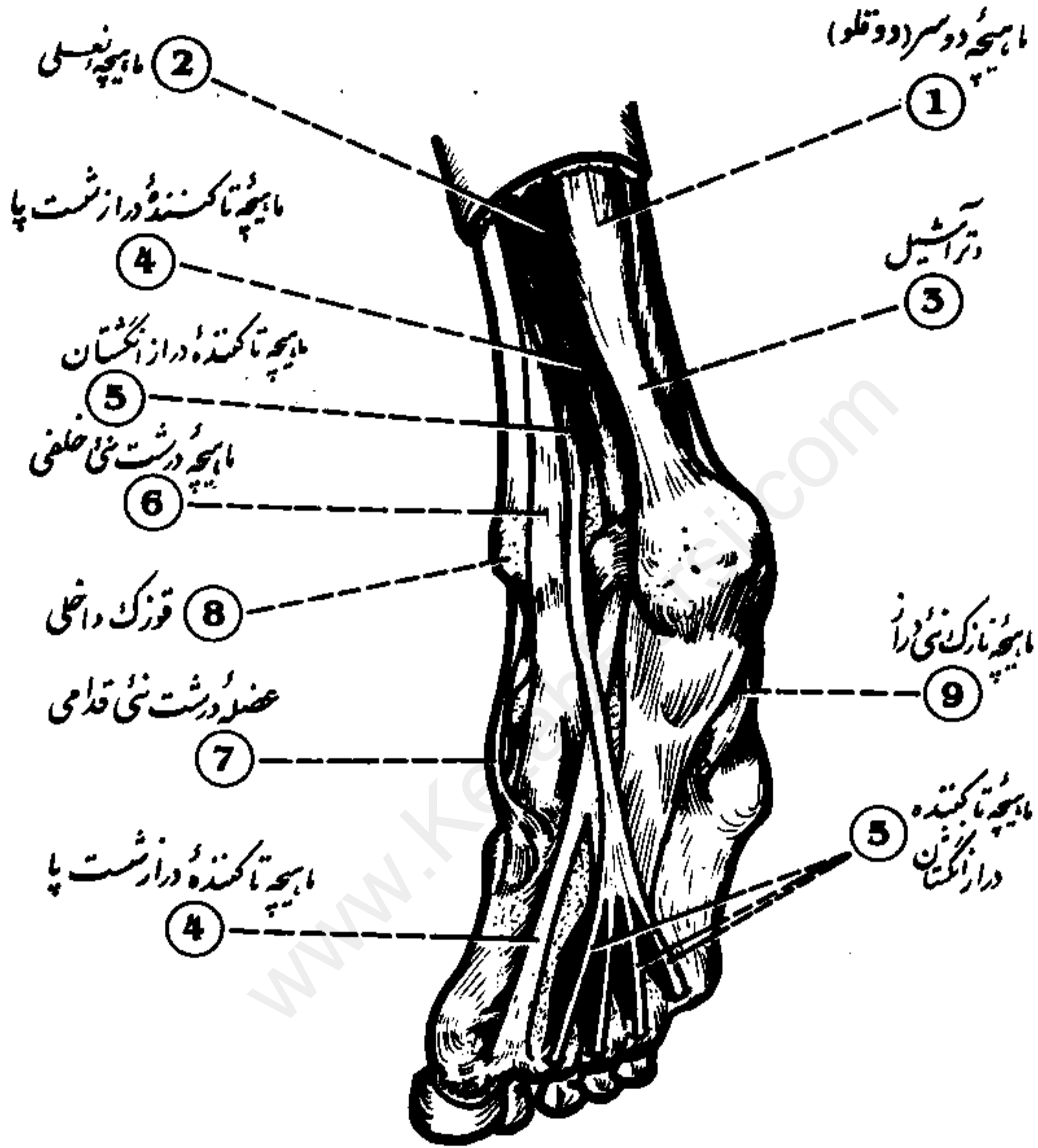
Muscles of the Plantar Surface of the Foot

عضلات کف پا



- | | | |
|--------------------------|---------------------------|---------------------------|
| 1 Abductor hallucis | 5 Lumbrical | 9 Flexor digitorum longus |
| 2 Flexor hallucis brevis | 6 Quadratus plantae | 10 Flexor hallucis longus |
| 3 Abductor digiti minimi | 7 Flexor digitorum brevis | 11 Adductor hallucis |
| 4 Flexor digiti minimi | 8 Calcaneus | 12 Peroneus longus |

Muscles and Tendons of the Leg and Foot (عضلات و اوتار ساق و کف پا)



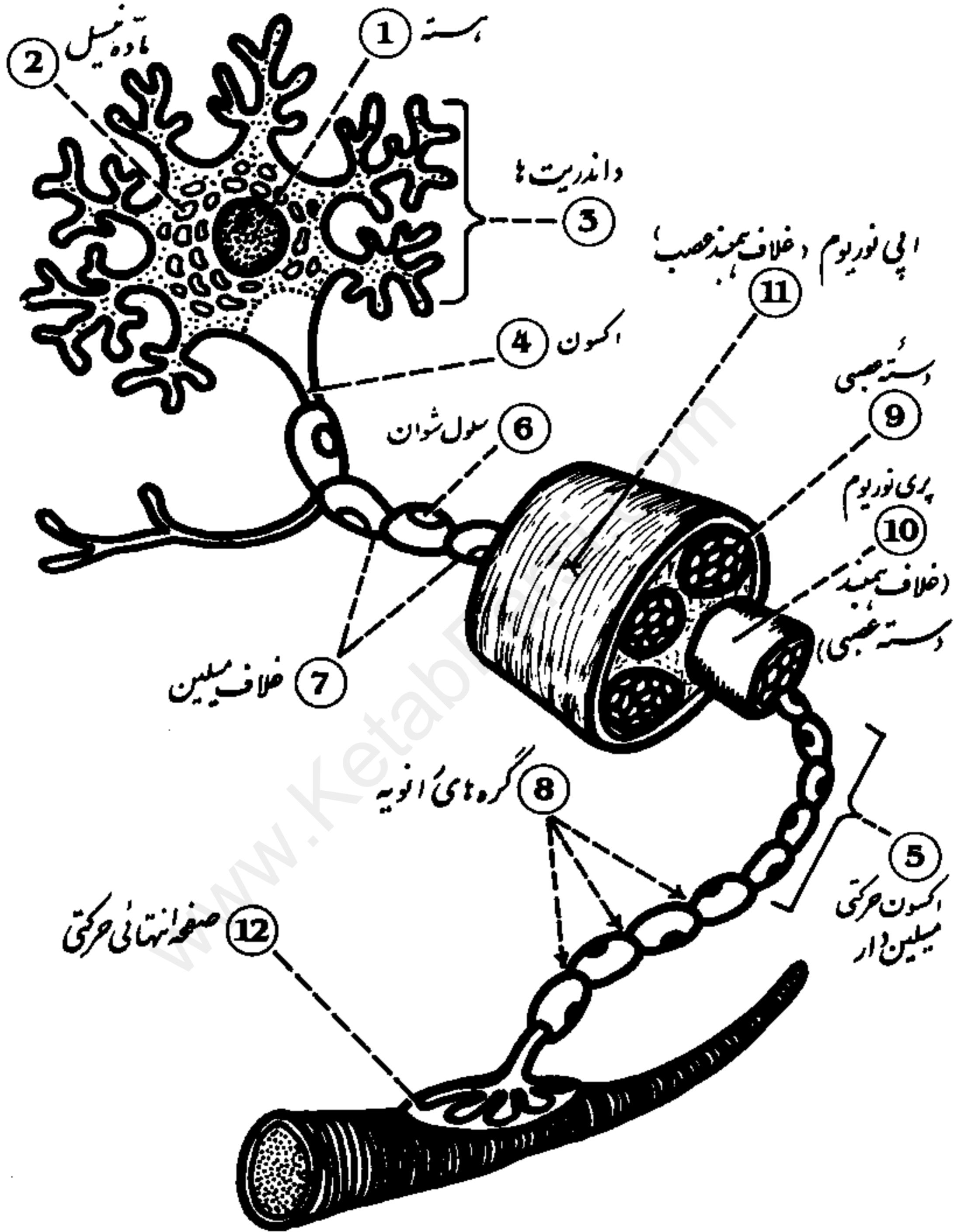
- 1 Gastrocnemius
2 Soleus
3 Achilles tendon

- 4 Flexor hallucis longus
5 Flexor digitorum longus
6 Tibialis posterior

- 7 Tibialis anterior
8 Medial malleolus
9 Peroneus longus

Histology of Nerve

(بافت شناسی عصب)

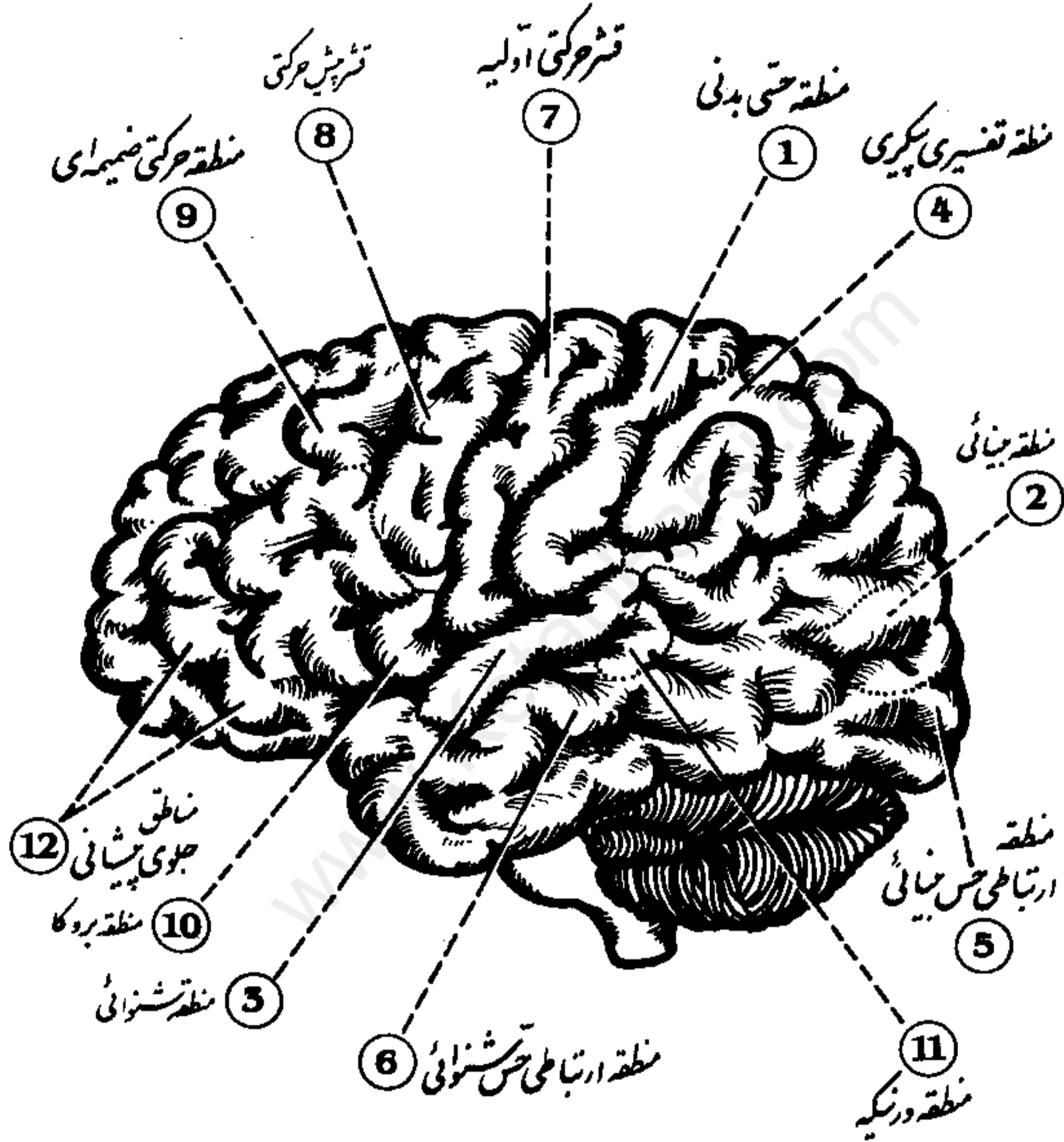


- | | | |
|-------------|-------------------------|--------------------|
| 1 Nucleus | 5 Myelinated motor axon | 9 Nerve fasciculus |
| 2 Nucleolus | 6 Schwann cell | 10 Perineurium |
| 3 Dendrites | 7 Myelin sheath | 11 Epineurium |
| 4 Axon | 8 Nodes of Ranvier | 12 Motor end plate |

Functional Map of the Cerebral Cortex

(Lateral View)

نقشه عملی قشر مغزی
(نمای خارجی)



- 1 Somatic sensory area
- 2 Visual area
- 3 Auditory area
- 4 Somatic association

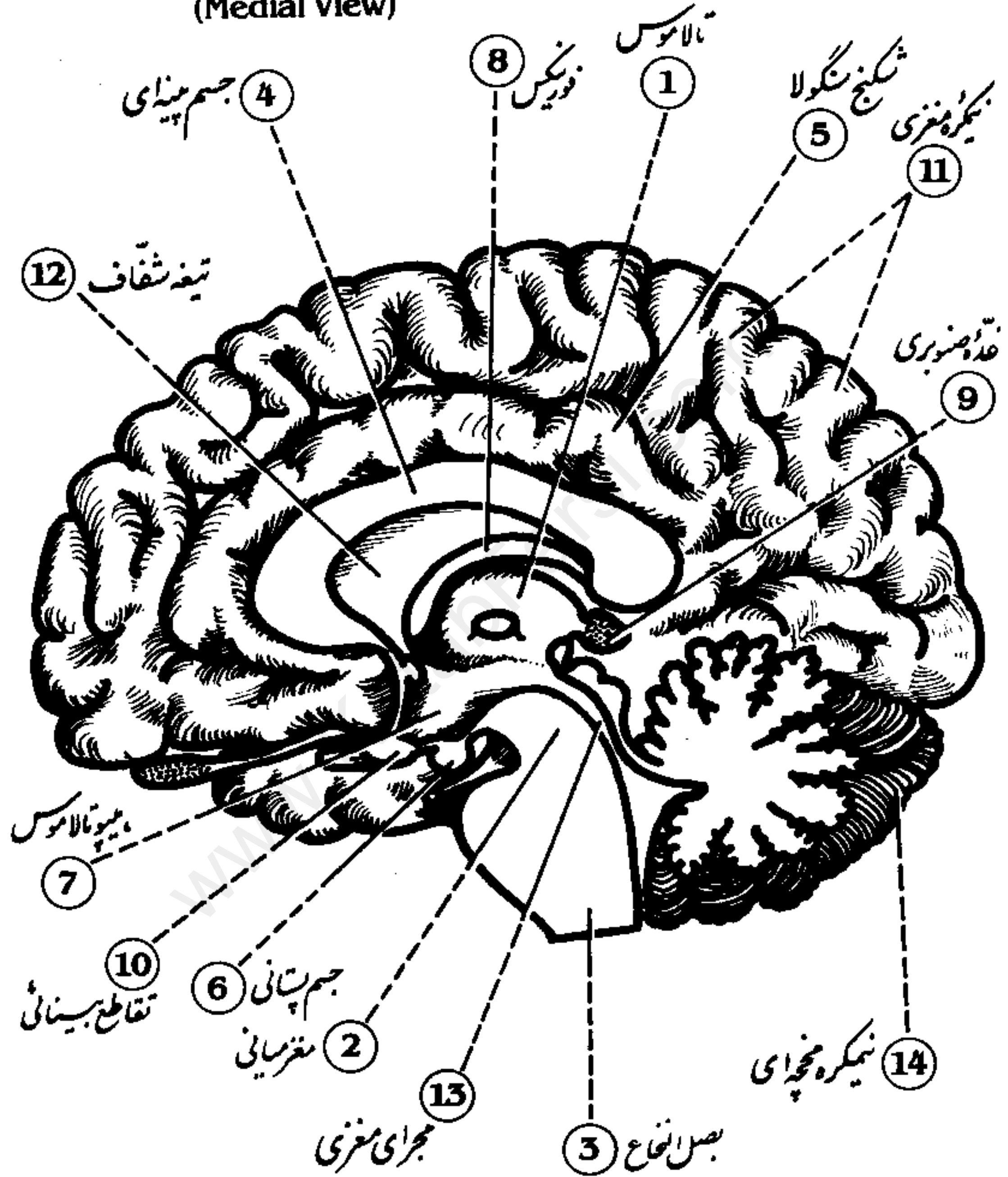
- 5 Visual association
- 6 Auditory association
- 7 Primary motor cortex
- 8 Premotor cortex

- 9 Supplementary motor area
- 10 Broca's area
- 11 Wernicke's area
- 12 Prefrontal areas

Midsagittal Section of Right Cerebral Hemisphere

(Medial View)

برش میانی نیمکره راست مغزی
(نمای داخلی)

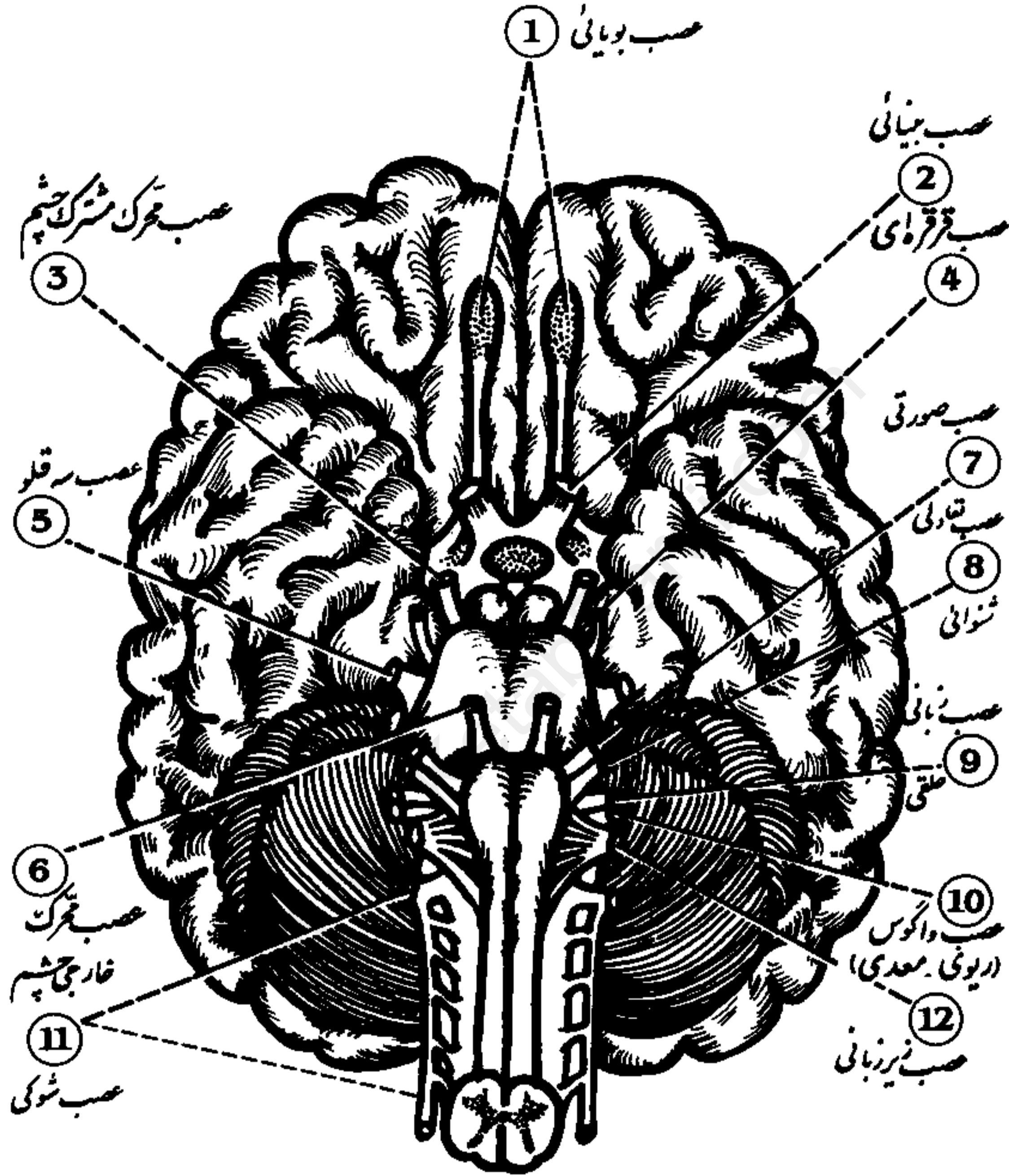


- | | | |
|---------------------|-------------------|--------------------------|
| 1 Thalamus | 6 Mammillary body | 11 Cerebral hemisphere |
| 2 Midbrain | 7 Hypothalamus | 12 Septum pellucidum |
| 3 Medulla oblongata | 8 Fornix | 13 Cerebral aqueduct |
| 4 Corpus callosum | 9 Pineal body | 14 Cerebellar hemisphere |
| 5 Cingulate gyrus | 10 Optic chiasma | |

Cranial Nerves

(Inferior View)

اعصاب مغزى (غداى تحتانى)



- 1 Olfactory nerve
- 2 Optic nerve
- 3 Oculomotor
- 4 Trochlear nerve

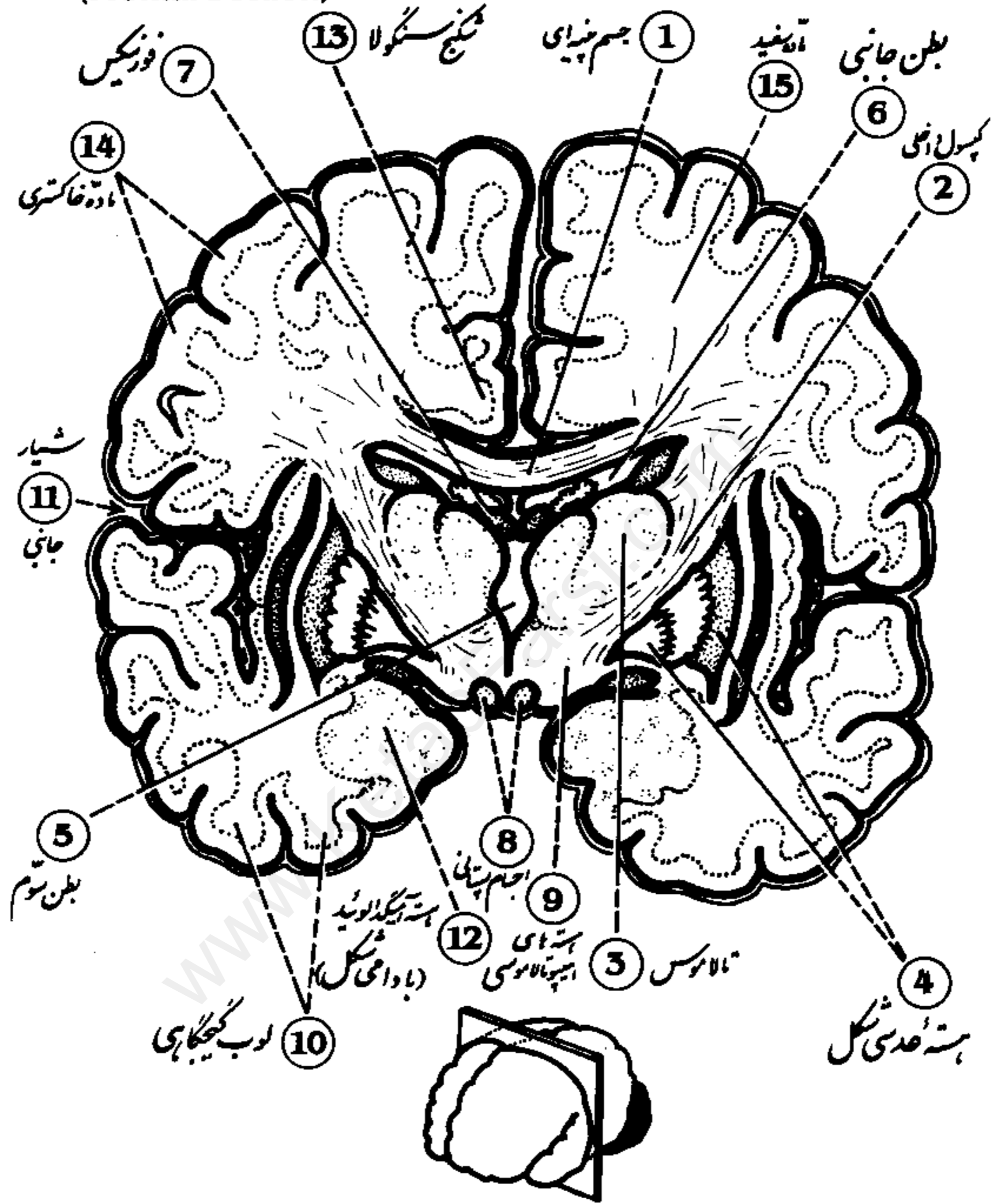
- 5 Trigeminal nerve
- 6 Abducens nerve
- 7 Facial nerve
- 8 Vestibulocochlear nerve

- 9 Glossopharyngeal nerve
- 10 Vagus nerve
- 11 Spinal accessory nerve
- 12 Hypoglossal nerve

Human Brain

(Frontal Section)

مغز انسان (قطع پیشانی)



- 1 Corpus callosum
- 2 Internal capsule
- 3 Thalamus
- 4 Lentiform nucleus
- 5 Third ventricle

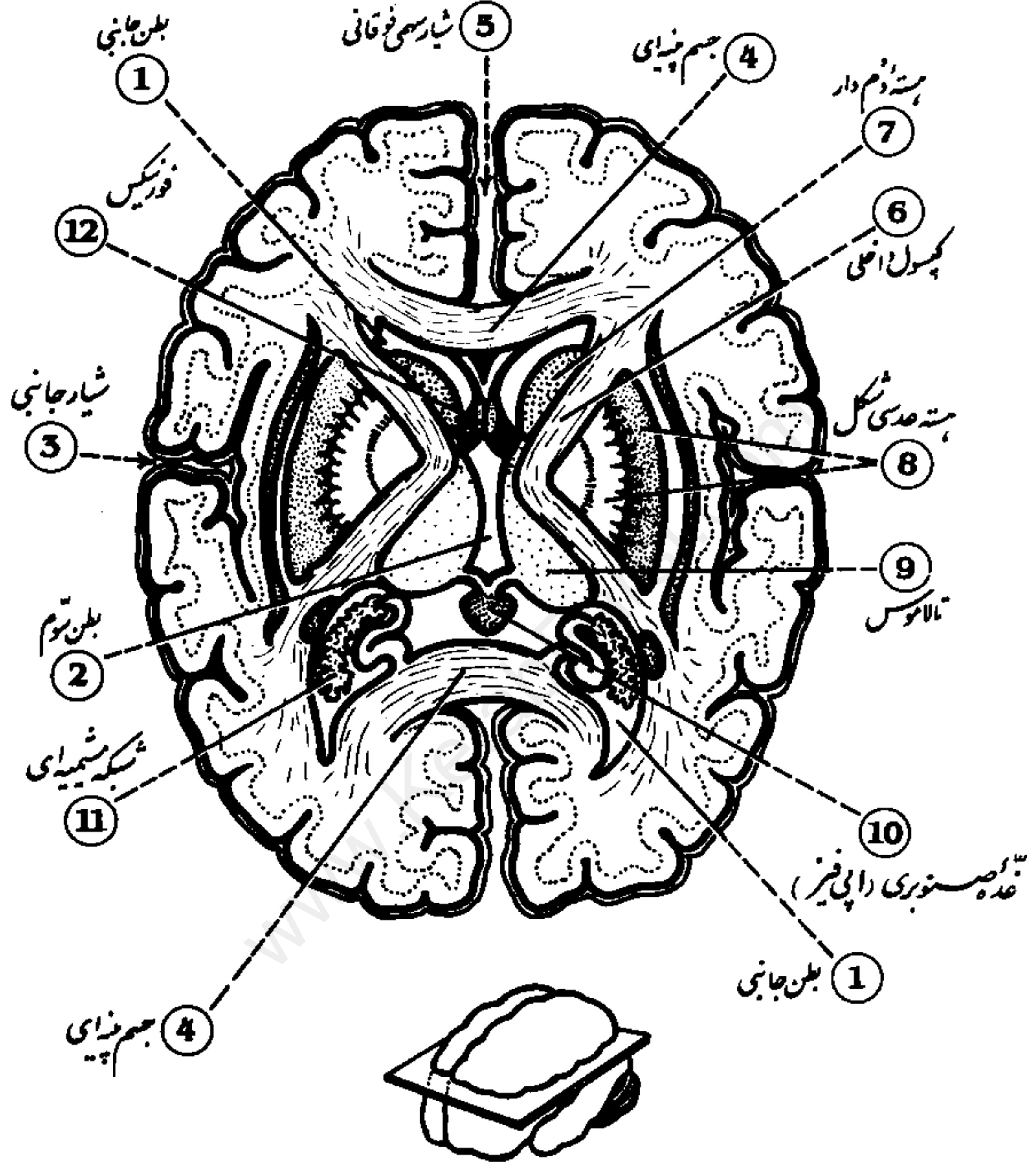
- 6 Lateral ventricle
- 7 Pons
- 8 Mammillary bodies
- 9 Hypothalamic nuclei
- 10 Temporal lobe

- 11 Lateral fissure
- 12 Amygdaloid nucleus
- 13 Cingulate gyrus
- 14 Gray matter
- 15 White matter

Human Brain

(Horizontal Section)

مغز انسان (تقاطع افقی)



- 1 Lateral ventricle
- 2 Third ventricle
- 3 Lateral fissure
- 4 Corpus callosum

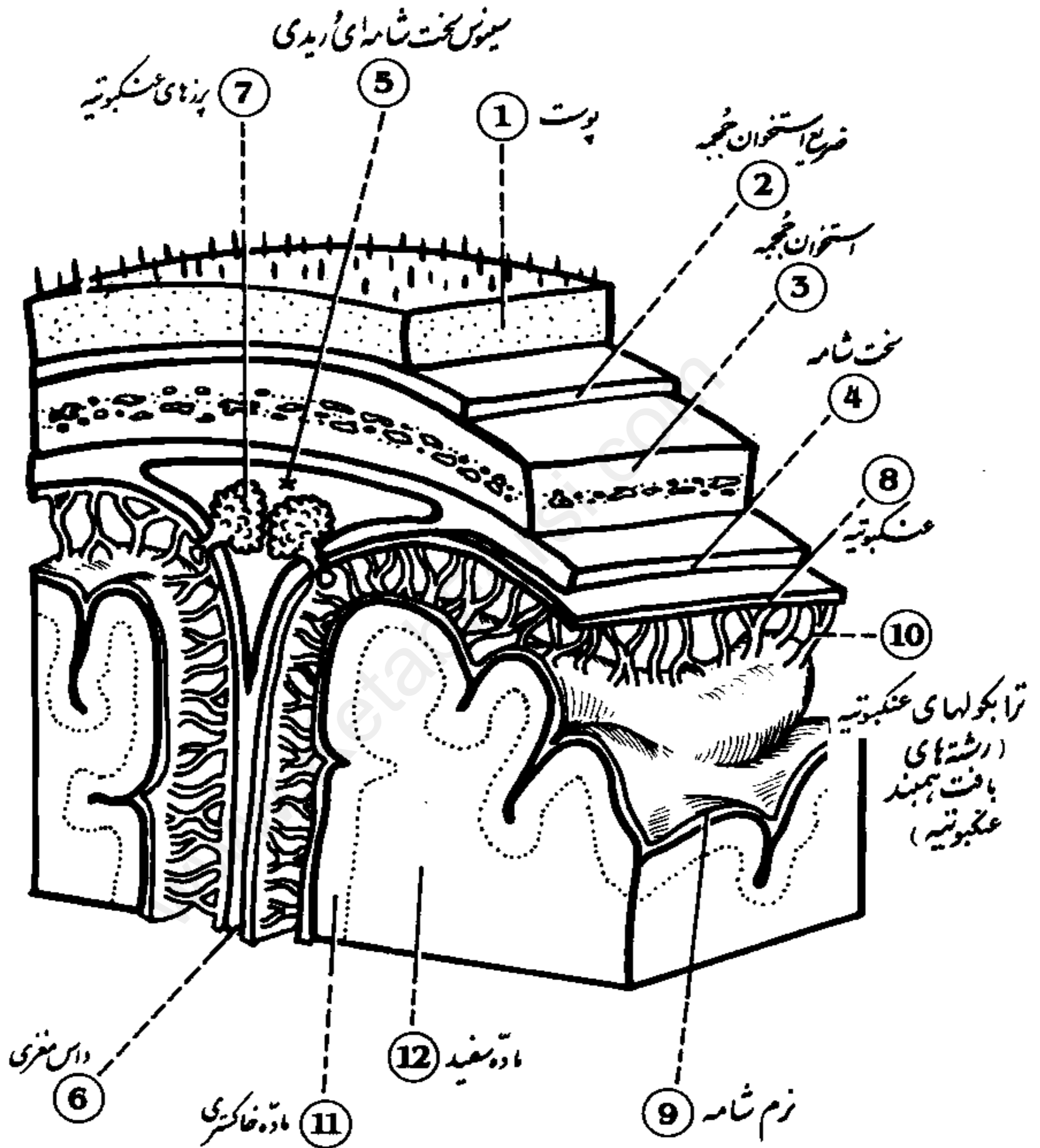
- 5 Superior sagittal fissure
- 6 Internal capsule
- 7 Caudate nucleus
- 8 Lentiform nucleus

- 9 Thalamus
- 10 Pineal body
- 11 Choroid plexus
- 12 Fornix

Skull and Brain

(Frontal-Sagittal Section)

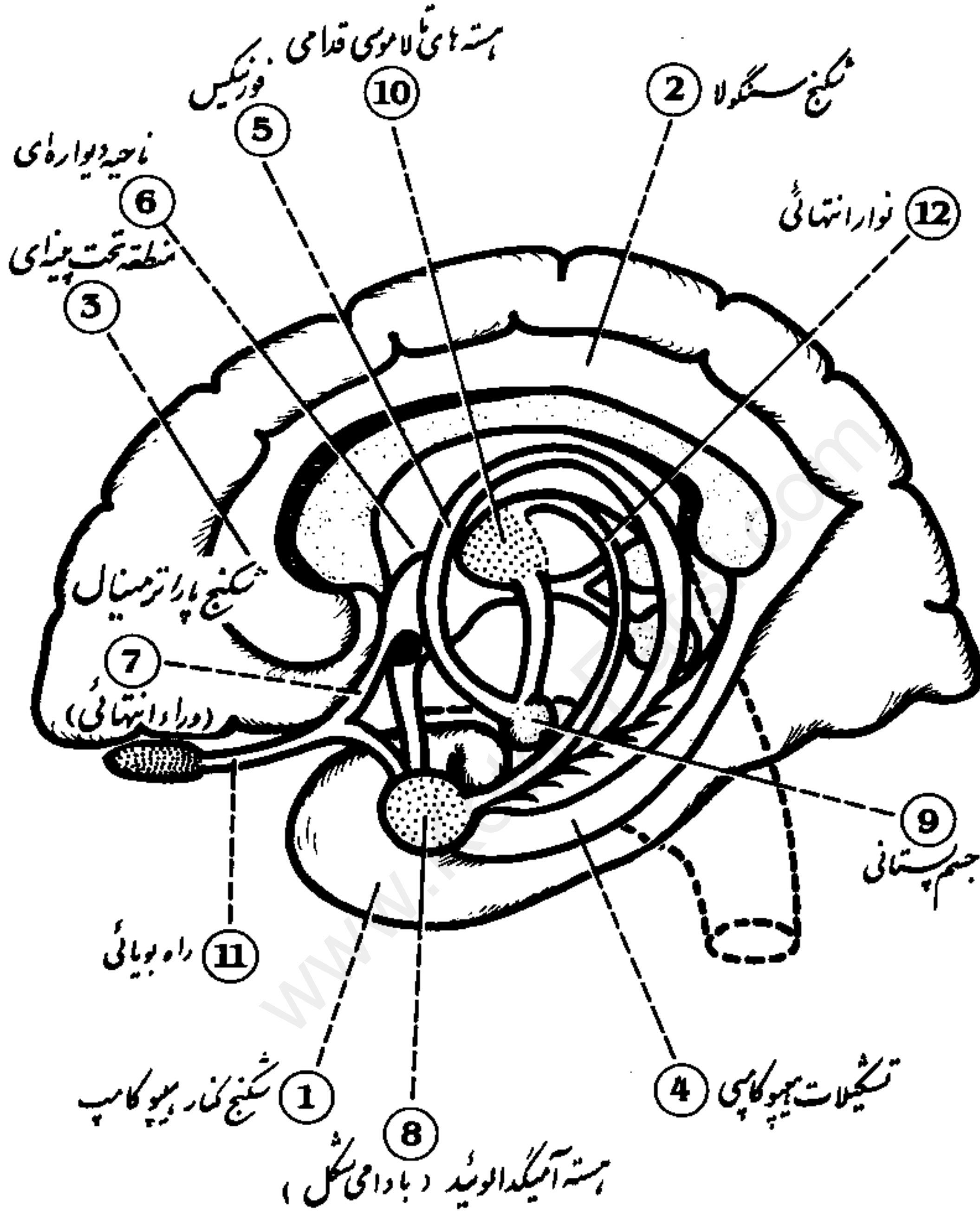
جُجمه و مغز (قطع پیشانی سهی)



- | | | |
|---------------|----------------------|-------------------------|
| 1 Skin | 5 Venous durai sinus | 9 Pia mater |
| 2 Pericranium | 6 Falx cerebri | 10 Arachnoid trabeculae |
| 3 Cranium | 7 Arachnoid villi | 11 Gray matter |
| 4 Dura mater | 8 Arachnoid mater | 12 White matter |

Limbic System

سیستم لیمبیک

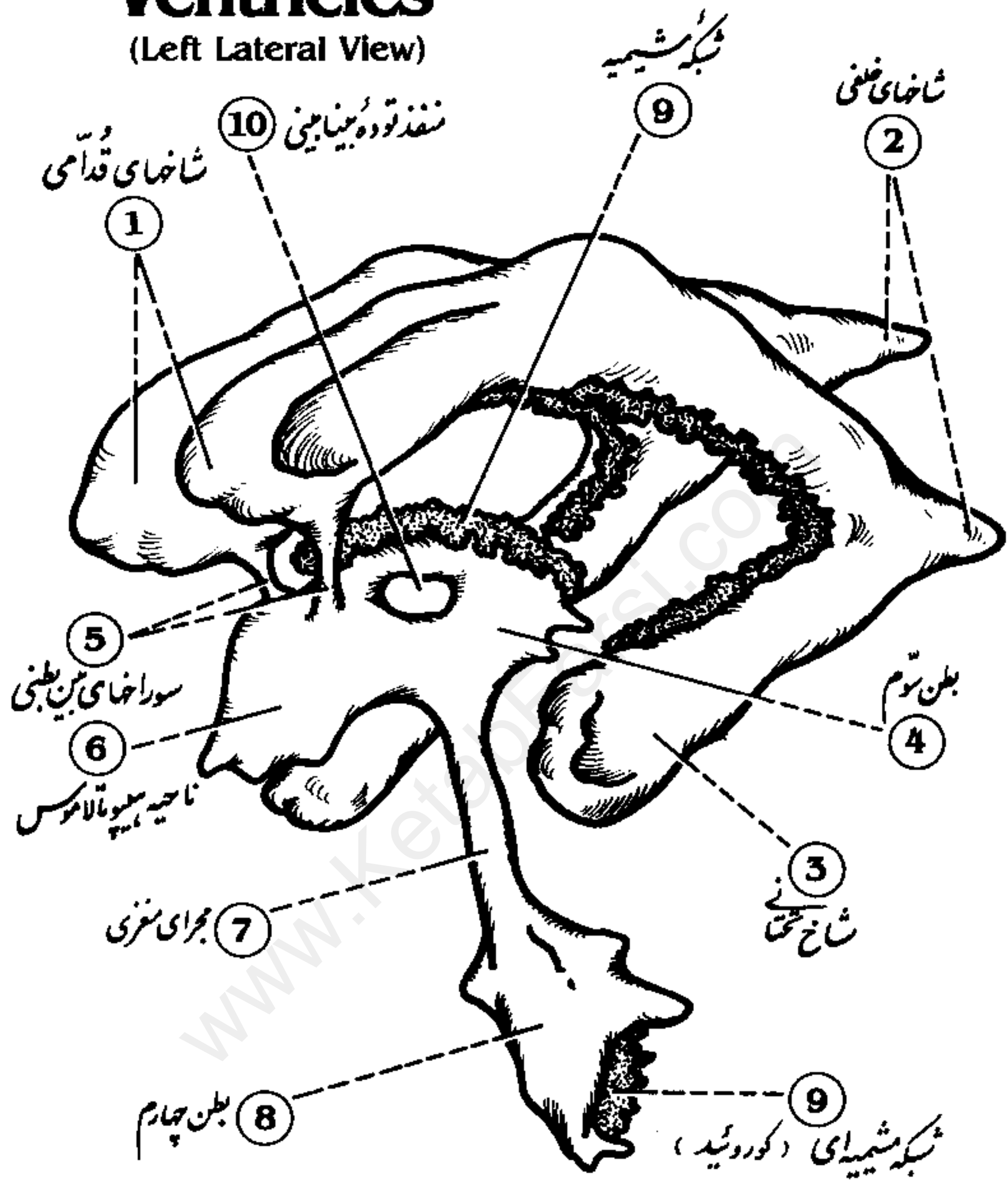


- 1 Parahippocampal gyrus
- 2 Cingulate gyrus
- 3 Subcallosal area
- 4 Hippocampal formation

- 5 Fornix
- 6 Septal region
- 7 Paraterminal gyrus
- 8 Amygdaloid nucleus

- 9 Mammillary body
- 10 Anterior thalamic nuclei
- 11 Olfactory tract
- 12 Stria terminalis

Cast of the Brain Ventricles (Left Lateral View) قالب بطن های مغزی (نمای جانبی چپ)

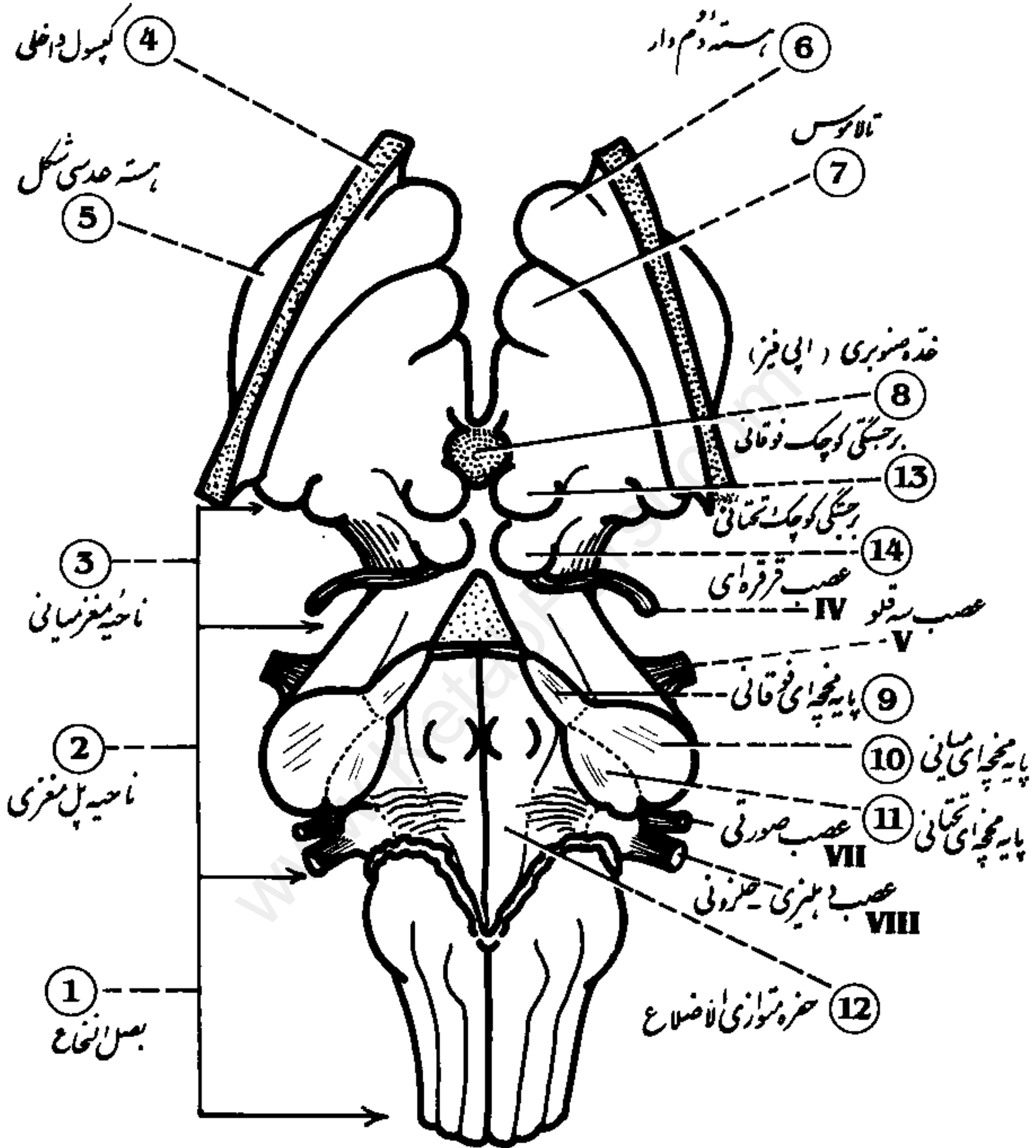


- | | |
|-----------------------------|-----------------------------|
| 1 Anterior horns | 6 Hypothalamus region |
| 2 Posterior horns | 7 Cerebral aqueduct |
| 3 Inferior horn | 8 Fourth ventricle |
| 4 Third ventricle | 9 Choroid plexus |
| 5 Interventricular foramina | 10 Massa intermedia opening |

Brain Stem

(Posterior view)

ساقه مغز (نمای خلفی)



- 1 Medulla oblongata
- 2 Pons region
- 3 Midbrain region
- 4 Internal capsule
- 5 Lentiform nucleus

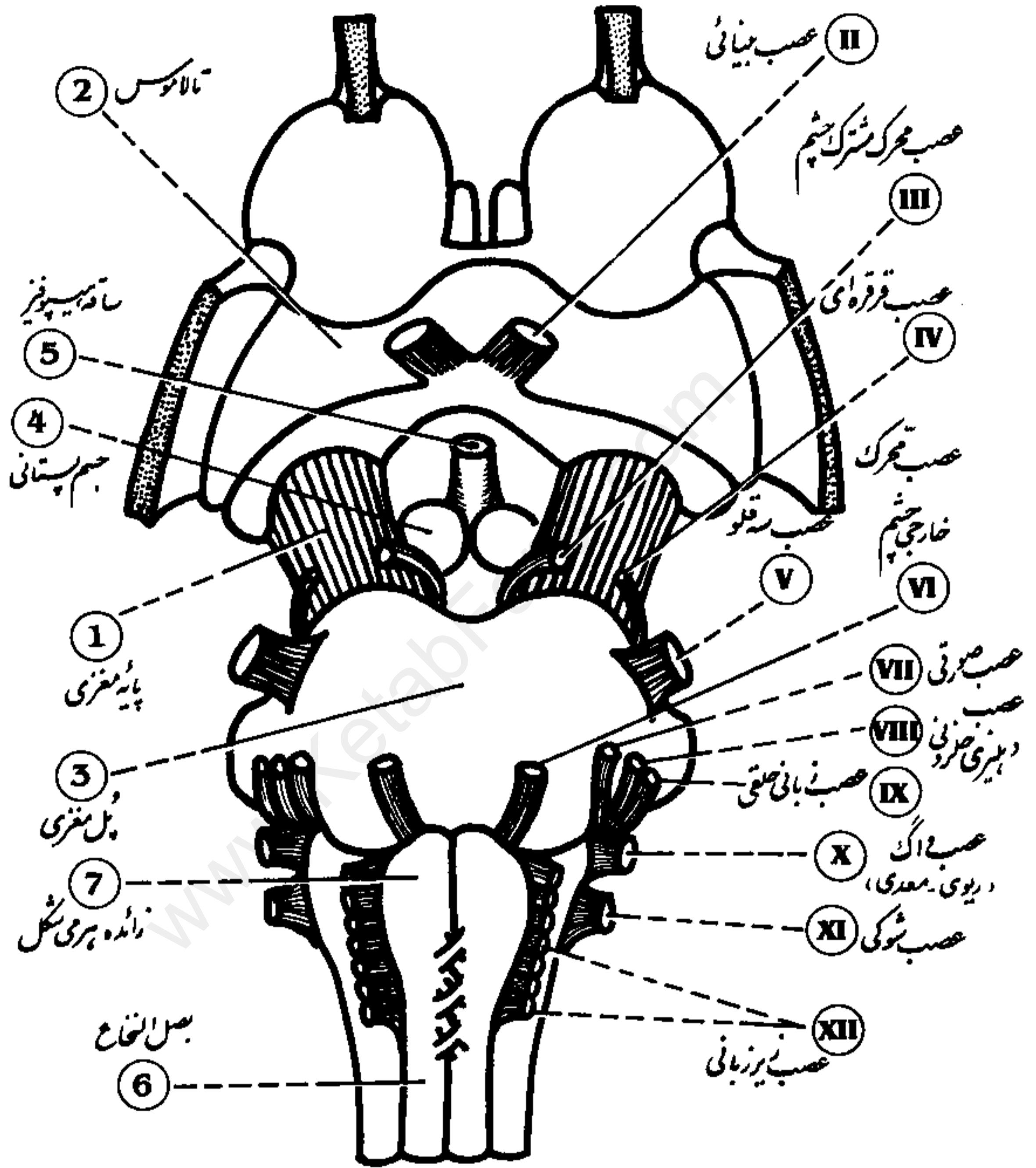
- 6 Caudate nucleus
- 7 Thalamus
- 8 Pineal body
- 9 Superior cerebellar peduncle
- 10 Middle cerebellar peduncle

- 11 Inferior cerebellar peduncle
- 12 Rhomboid fossa
- 13 Superior colliculus
- 14 Inferior colliculus

Brain Stem

(Anterior View)

ساقه مغز (نمای قدامی)



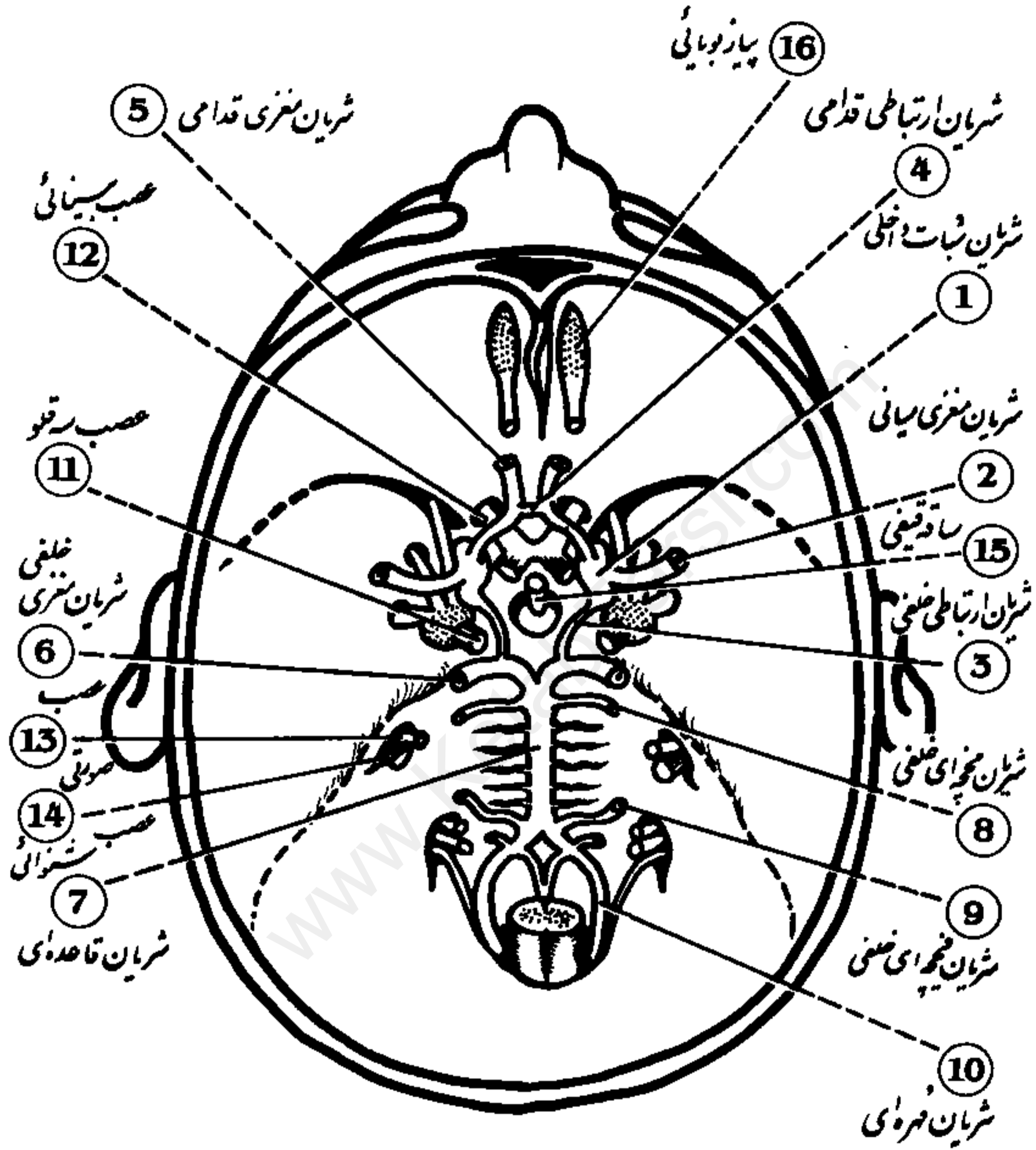
- 1 Cerebral peduncle
- 2 Thalamus
- 3 Pons
- 4 Mammillary body

- 5 Pituitary stalk
- 6 Medulla oblongata
- 7 Pyramid

Arterial Circle (of Willis)

(Base of Cranium)

حلقه شریانی ویلیس (قاعده جمجمه)

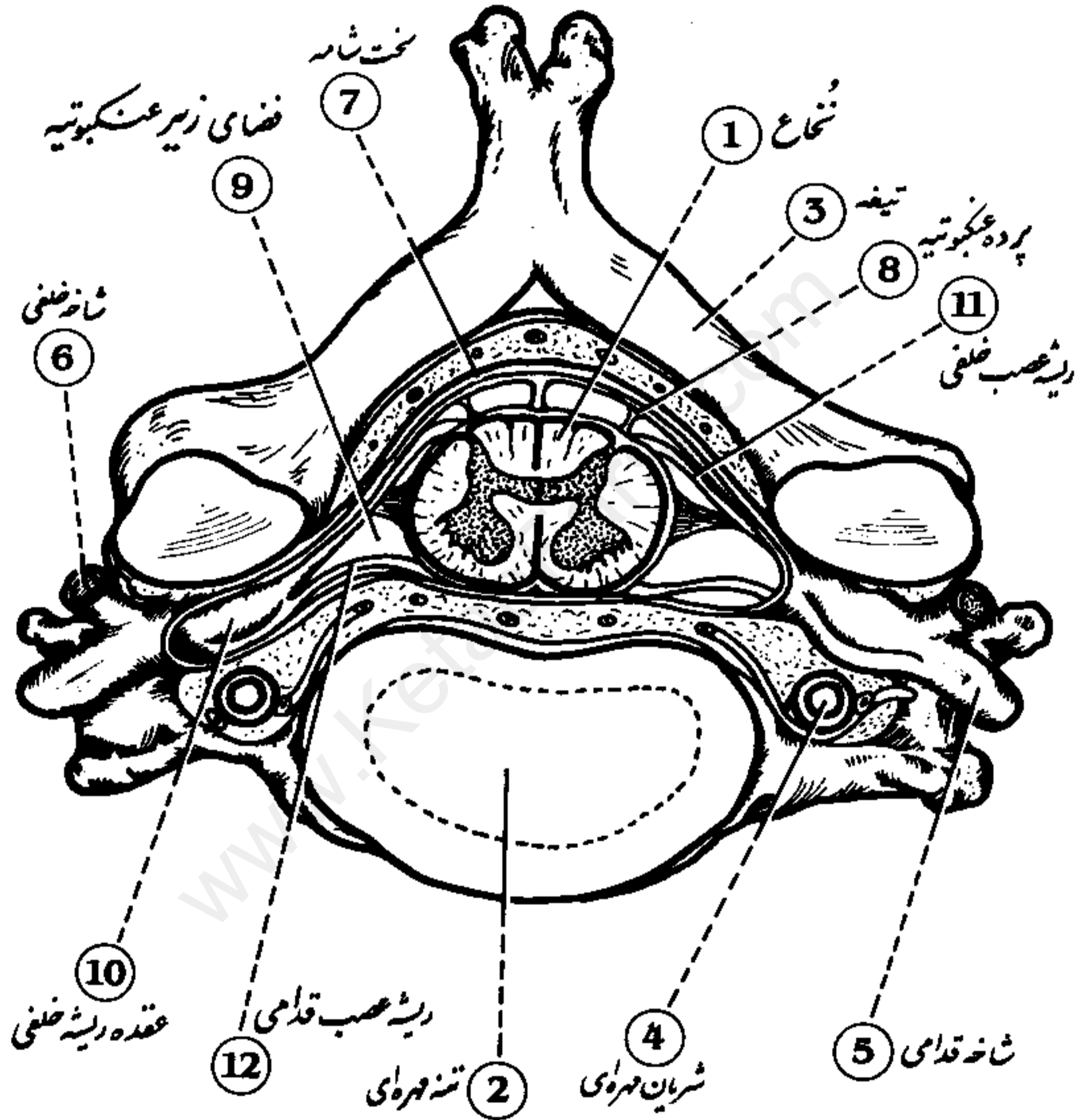


- | | | | |
|---------------------------|-----------------------|------------------------|-----------------------|
| 1 Internal carotid | 5 Anterior cerebral | 9 Posterior cerebellar | 13 Facial nerve |
| 2 Middle cerebral | 6 Posterior cerebral | 10 Vertebral | 14 Auditory nerve |
| 3 Posterior communicating | 7 Basilar | 11 Trigeminal nerve | 15 Infundibular stalk |
| 4 Anterior communicating | 8 Anterior cerebellar | 12 Optic nerve | 16 Olfactory bulb |

Superior View of Spinal Cord

(At Cervical Level)

نمای فوقانی نخاع (در سطح مهره گردنی)



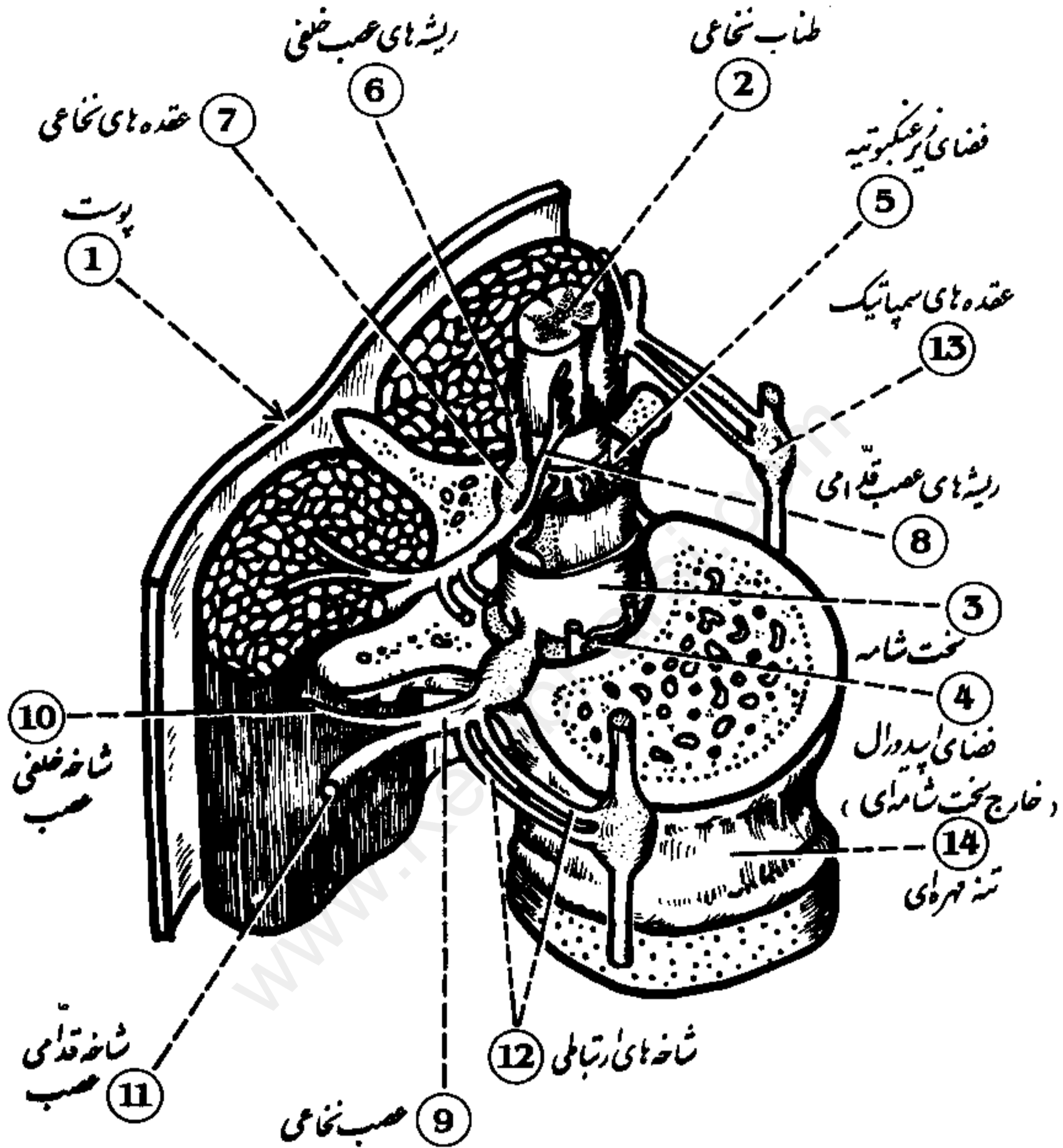
- 1 Spinal cord
- 2 Vertebral body
- 3 Lamina
- 4 Vertebral artery

- 5 Anterior ramus
- 6 Posterior ramus
- 7 Dura mater
- 8 Arachnoid membrane

- 9 Subarachnoid space
- 10 Posterior root ganglion
- 11 Posterior nerve root
- 12 Anterior nerve root

Relationships of Spinal Cord

ارتباطات نخاع



- 1 Skin
- 2 Spinal cord
- 3 Dura mater
- 4 Epidural space
- 5 Subarachnoid space

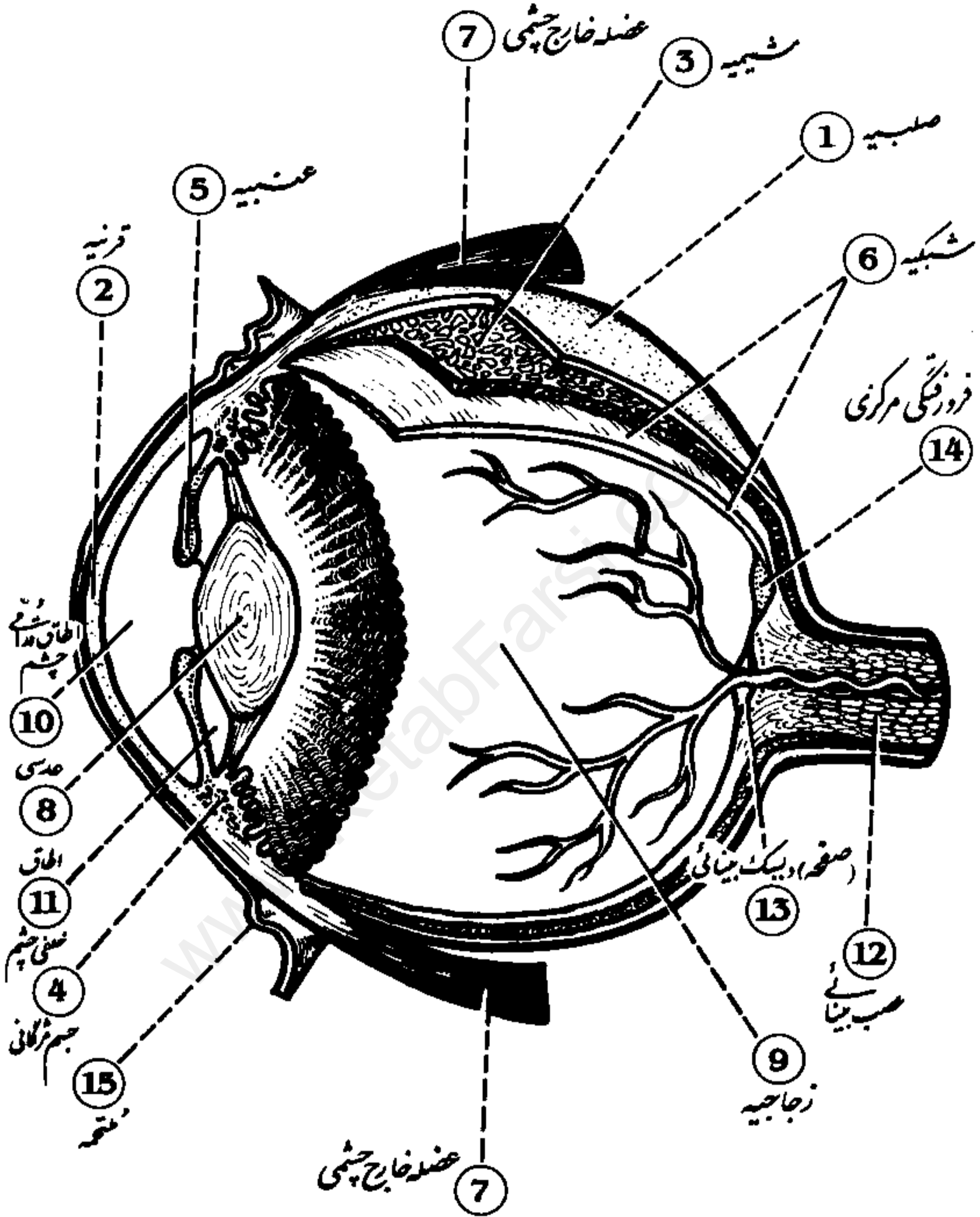
- 6 Posterior nerve roots
- 7 Spinal ganglia
- 8 Anterior nerve roots
- 9 Spinal nerve
- 10 Posterior ramus

- 11 Anterior ramus
- 12 Rami communicantes
- 13 Sympathetic ganglia
- 14 Vertebral body

Eyeball

(Cross Section)

کرہ چشم (قطع عرضی)

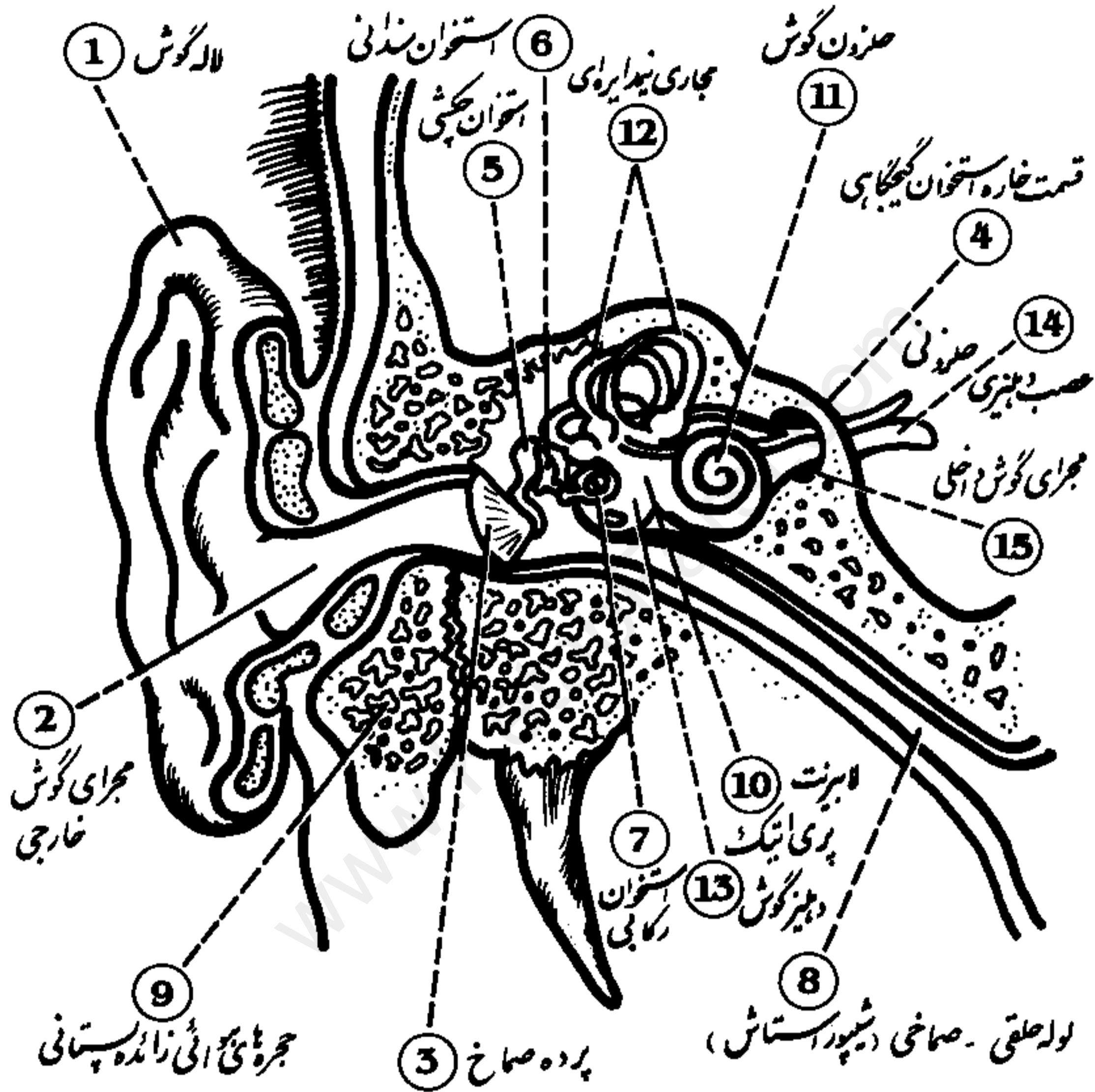


- | | | |
|----------------|----------------------|----------------------|
| 1 Sclera | 6 Retina | 11 Posterior chamber |
| 2 Cornea | 7 Extraocular muscle | 12 Optic nerve |
| 3 Choroid | 8 Lens | 13 Optic disk |
| 4 Ciliary body | 9 Vitreous chamber | 14 Fovea centralis |
| 5 Iris | 10 Anterior chamber | 15 Conjunctiva |

گوش خارجی، میانی و داخلی (قطع پیشانی)

External, Middle, and Inner Ear

(Frontal Section)



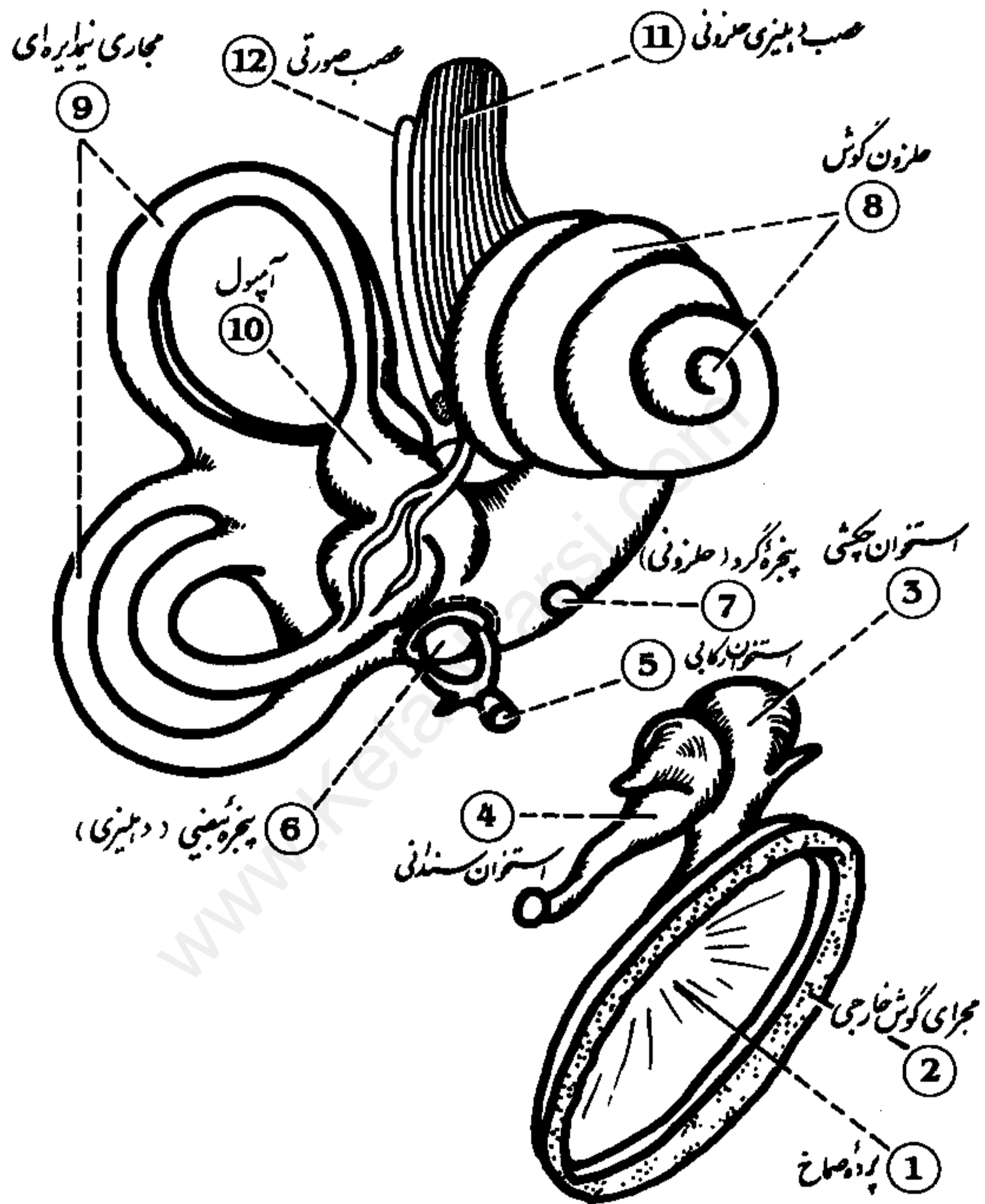
- 1 Auricle
- 2 External auditory meatus
- 3 Tympanic membrane
- 4 Petrous temporal bone
- 5 Malleus

- 6 Incus
- 7 Stapes
- 8 Pharyngotympanic tube
- 9 Mastoid air cells
- 10 Periotic labyrinth

- 11 Cochlea
- 12 Semicircular canals
- 13 Vestibule
- 14 Vestibulocochlear nerve
- 15 Internal auditory meatus

Inner Ear

گوشش داخلی



- 1 Tympanic membrane
- 2 External auditory meatus
- 3 Malleus
- 4 Incus

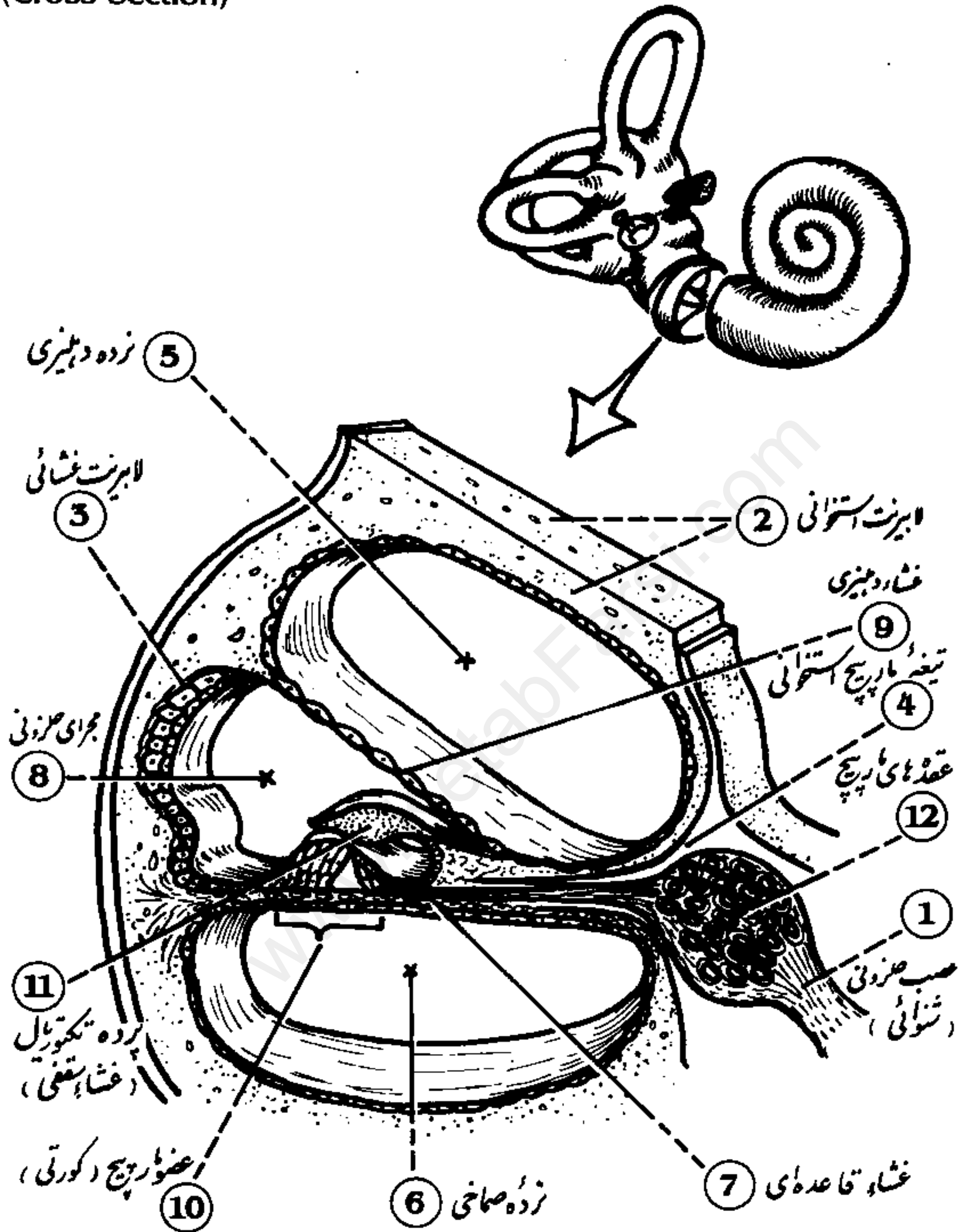
- 5 Stapes
- 6 Oval window
- 7 Round window
- 8 Cochlea

- 9 Semicircular canals
- 10 Ampulla
- 11 Vestibulocochlear nerve
- 12 Facial nerve

Cochlea

(Cross Section)

حلزون گوش (برش عرضی)

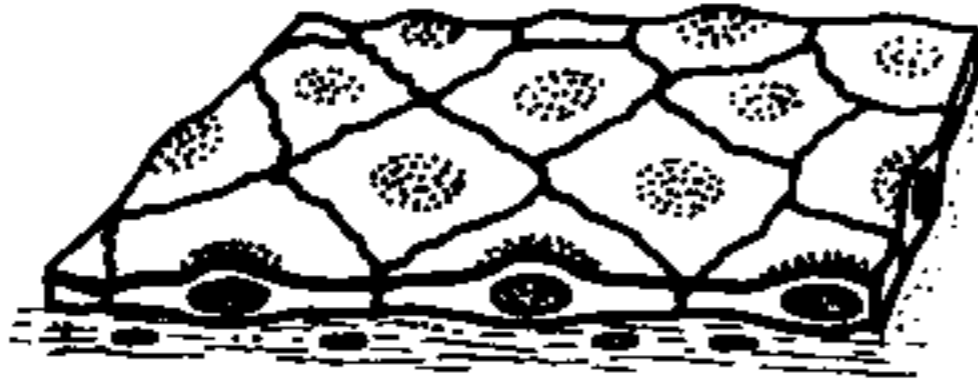


- | | | |
|------------------------|--------------------|-----------------------|
| 1 Cochlear nerve | 8 Scala vestibuli | 9 Vestibular membrane |
| 2 Bony labyrinth | 6 Scala tympani | 10 Organ of Corti |
| 3 Membranous labyrinth | 7 Basilar membrane | 11 Tectorial membrane |
| 4 Bony spiral lamina | 8 Cochlear duct | 12 Spiral ganglia |

Epithelium

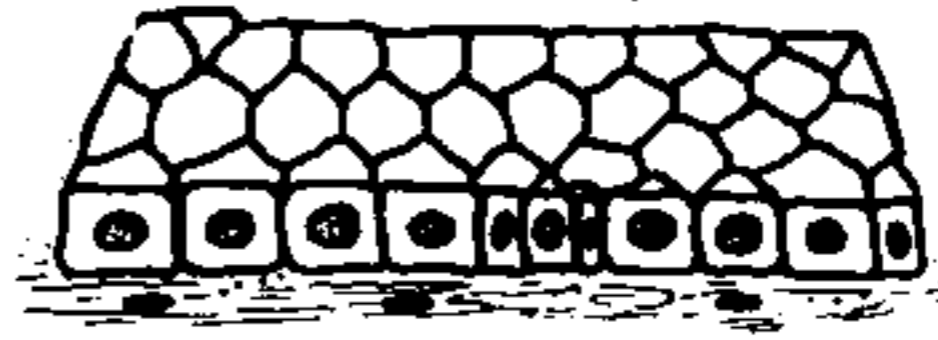بافت پوششی

بافت پوششی ساده سنگفرشی

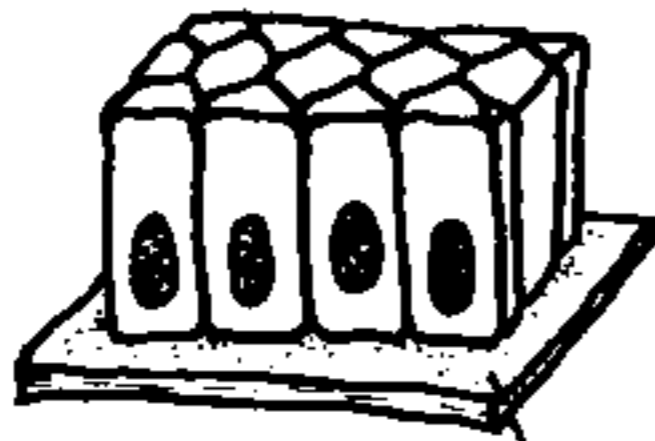


2

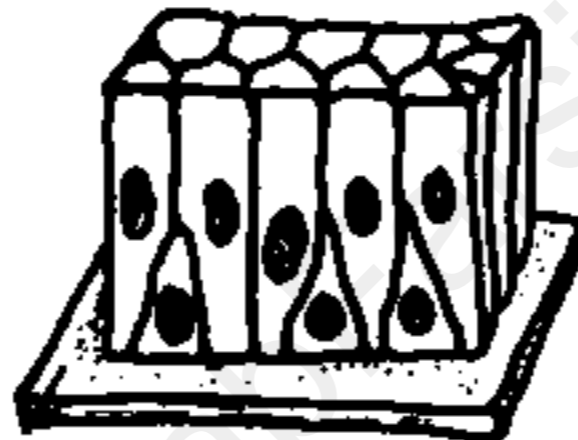
بافت پوششی ساده مکعبی



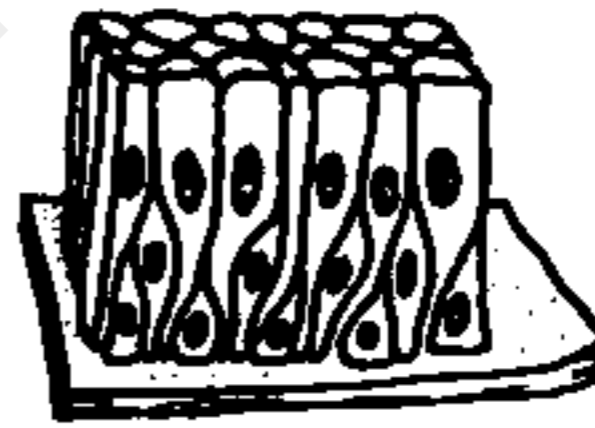
3



4



5



بافت پوششی ساده استوانه‌ای

1

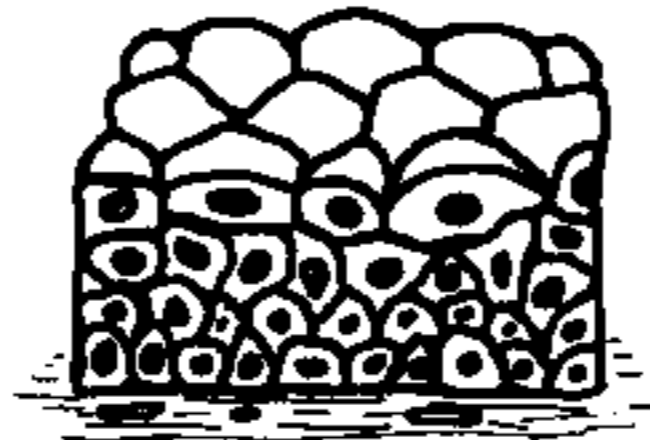
غشاء پایه

بافت پوششی مُطبّق کاذب



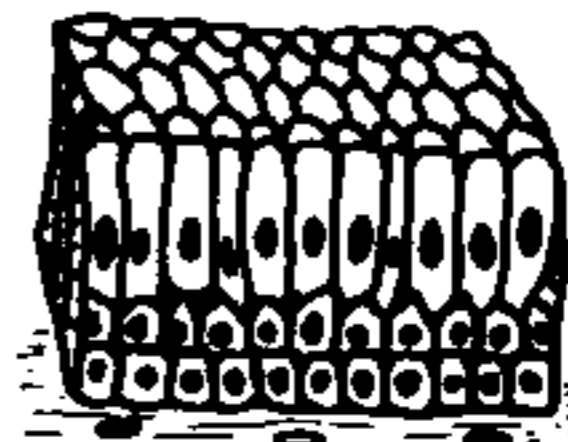
6

بافت پوششی مُطبّق سنگفرشی



7

بافت پوششی مُطبّق مکعبی



8

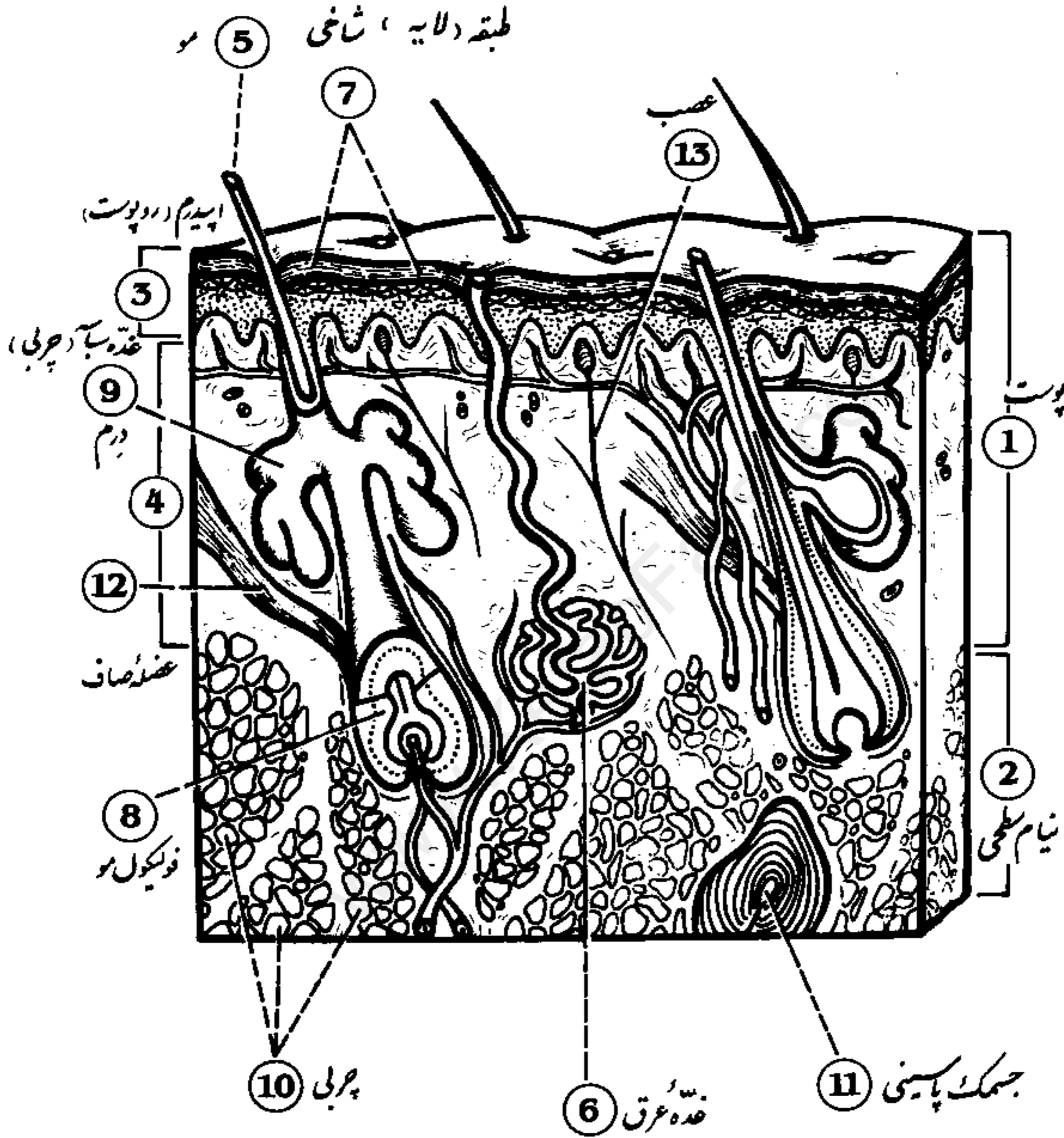
بافت پوششی مُطبّق استوانه‌ای

- 1 Basal lamina
- 2 Simple squamous
- 3 Simple cuboidal
- 4 Simple columnar

- 5 Pseudostratified
- 6 Stratified squamous
- 7 Stratified cuboidal
- 8 Stratified columnar

Integument

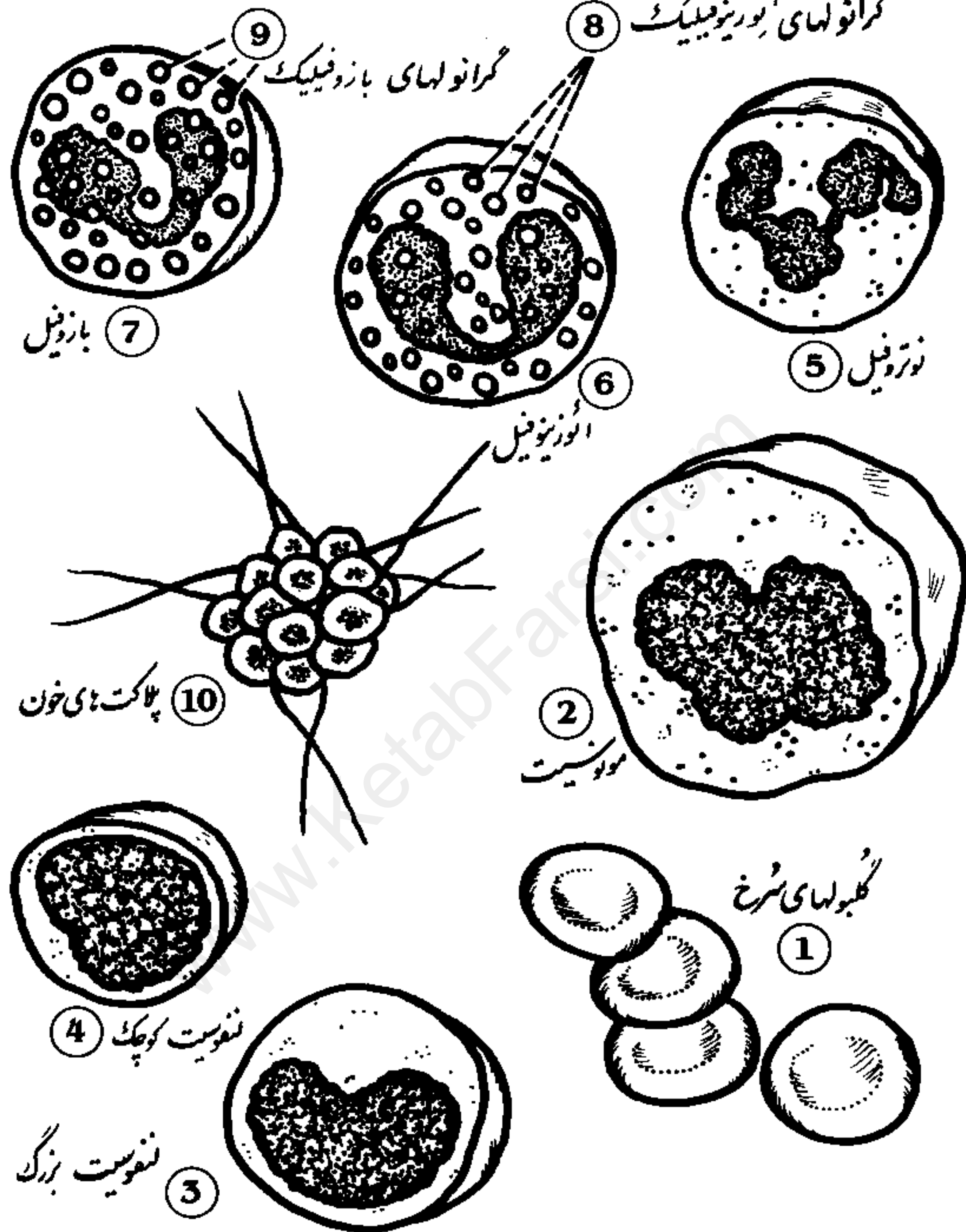
پوست



- | | | |
|----------------------|-------------------|-----------------------|
| 1 Skin | 6 Sweat gland | 11 Pacinian corpuscle |
| 2 Superficial fascia | 7 Stratum corneum | 12 Smooth muscle |
| 3 Epidermis | 8 Hair follicle | 13 Nerve |
| 4 Dermis | 9 Sebaceous gland | |
| 5 Hair | 10 Fat | |

Formed Elements of the Blood

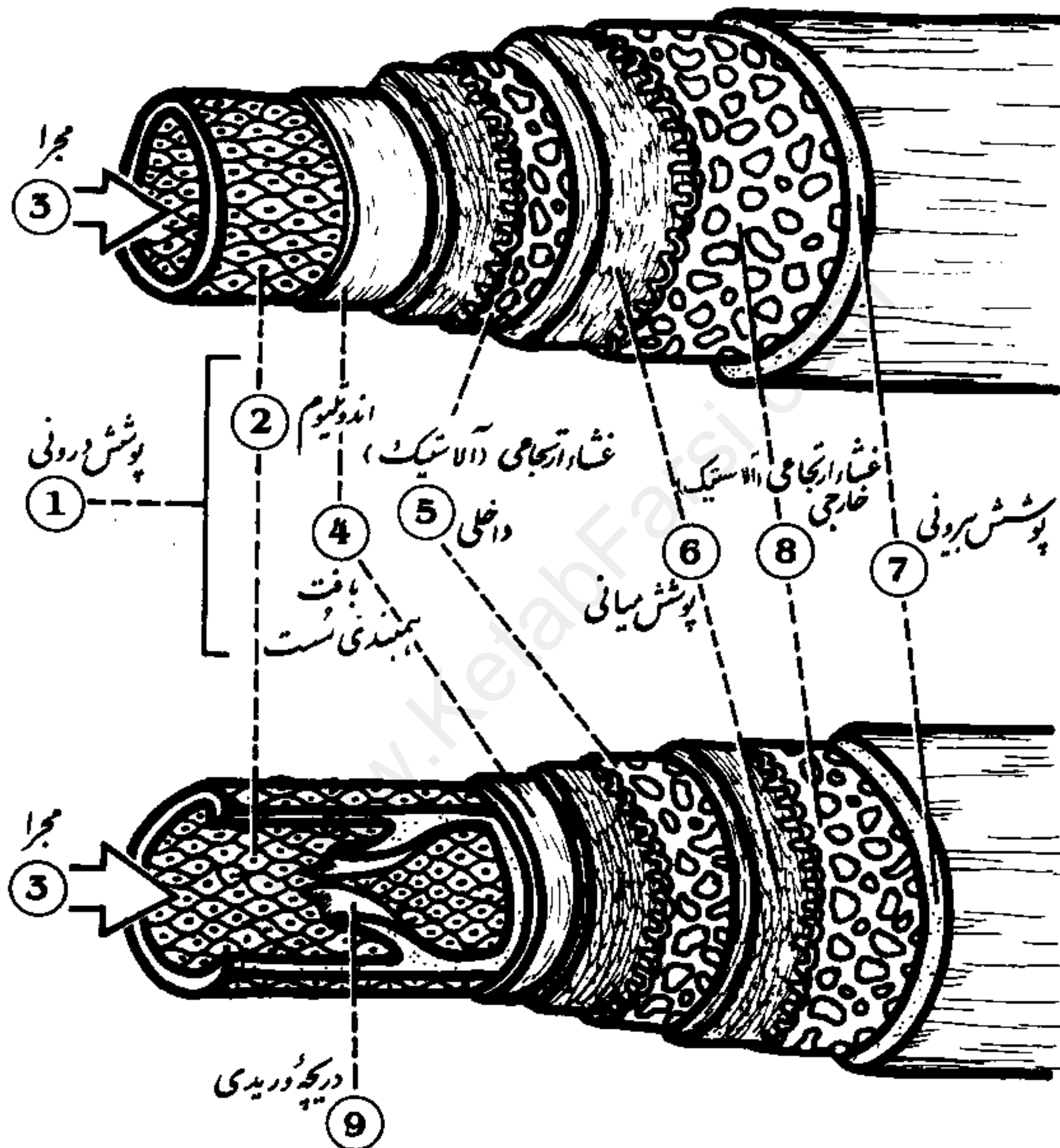
عناصر تشکیل دهنده خون



- 1 Red blood cells
- 2 Monocyte
- 3 Large lymphocyte
- 4 Small lymphocyte
- 5 Neutrophil

- 6 Eosinophil
- 7 Basophil
- 8 Eosinophilic granules
- 9 Basophilic granules
- 10 Blood platelets

مقایسه شریک و سیاهرگ Comparison of Artery and Vein

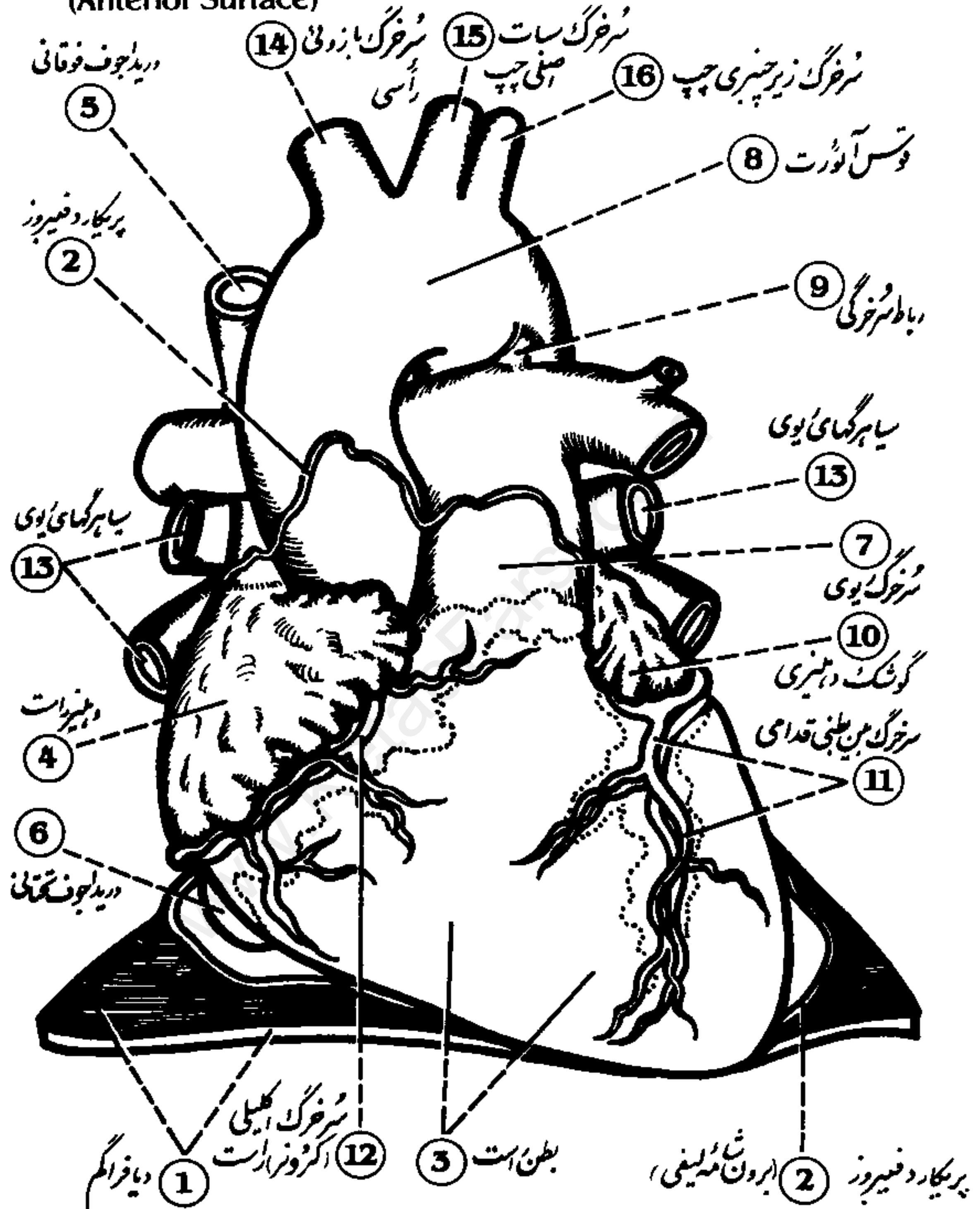


- | | |
|-----------------------------|-----------------------------|
| 1 Tunica intima | 6 Tunica media |
| 2 Endothelium | 7 Tunica externa |
| 3 Lumen | 8 External elastic membrane |
| 4 Loose connective tissue | 9 Venous valve |
| 5 Internal elastic membrane | |

Human Heart

قلب انسان (سطح قدامی)

(Anterior Surface)

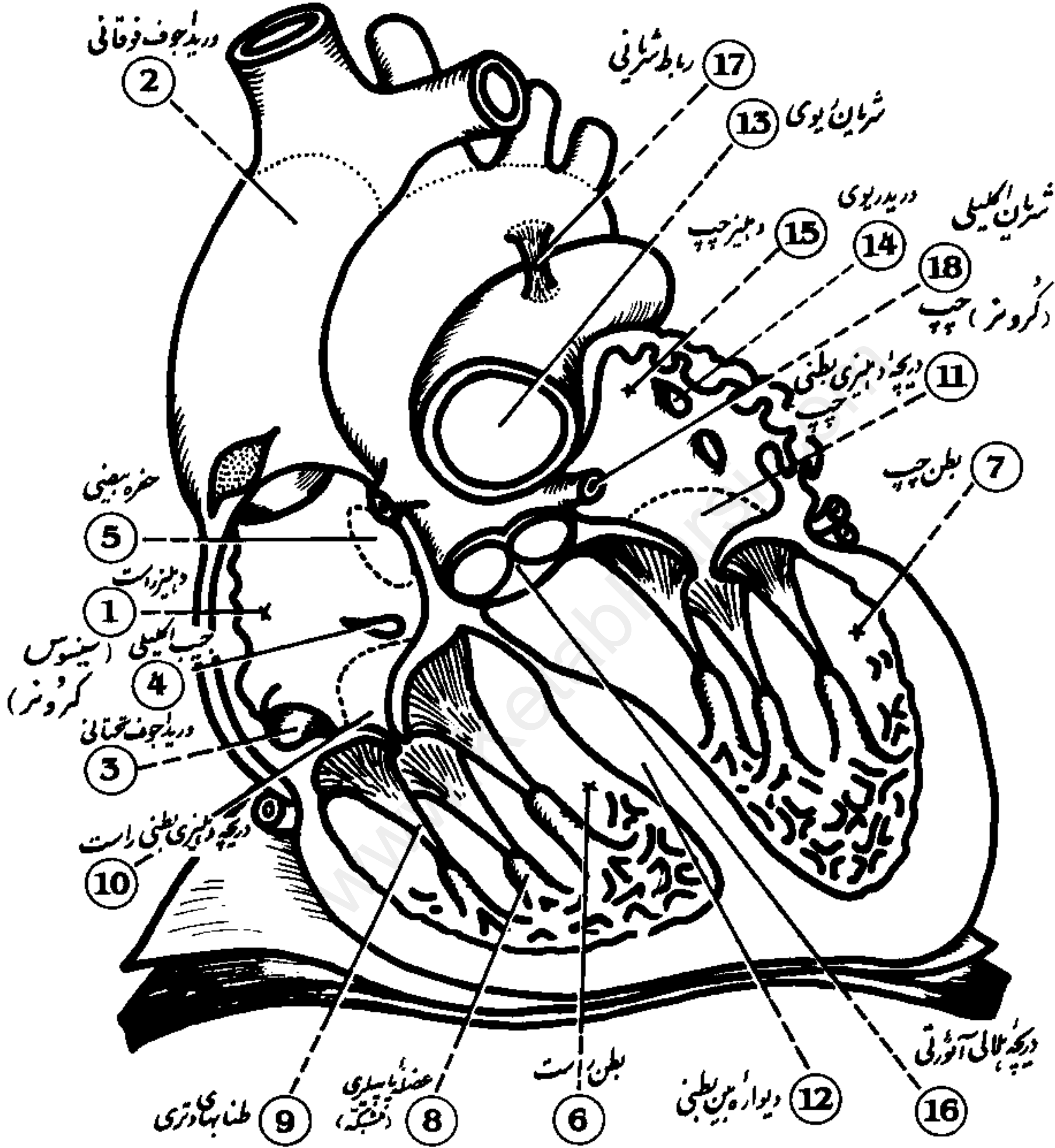


- | | | | |
|-----------------------|----------------------|-------------------------------------|-------------------------------|
| 1 Diaphragm | 5 Superior vena cava | 9 Ligamentum arteriosum | 13 Pulmonary veins |
| 2 Fibrous pericardium | 6 Inferior vena cava | 10 Auricle | 14 Brachiocephalic artery |
| 3 Right ventricle | 7 Pulmonary artery | 11 Anterior Interventricular artery | 15 Left common carotid artery |
| 4 Right atrium | 8 Aortic arch | 12 Right coronary artery | 16 Left subclavian artery |

Human Heart

(Internal Structure)

قلب انسان (ساختار درونی)



- | | | | |
|----------------------|---------------------------------|--------------------------------|---------------------------|
| 1 Right atrium | 6 Right ventricle | 11 Left atrioventricular valve | 18 Aortic semilunar valve |
| 2 Superior vena cava | 7 Left ventricle | 12 Interventricular septum | 17 Ligamentum arteriosum |
| 3 Inferior vena cava | 8 Papillary muscle | 13 Pulmonary artery | 18 Left coronary artery |
| 4 Coronary sinus | 9 Chordae tendinae | 14 Pulmonary vein | |
| 5 Fossa ovalis | 10 Right atrioventricular valve | 15 Left atrium | |